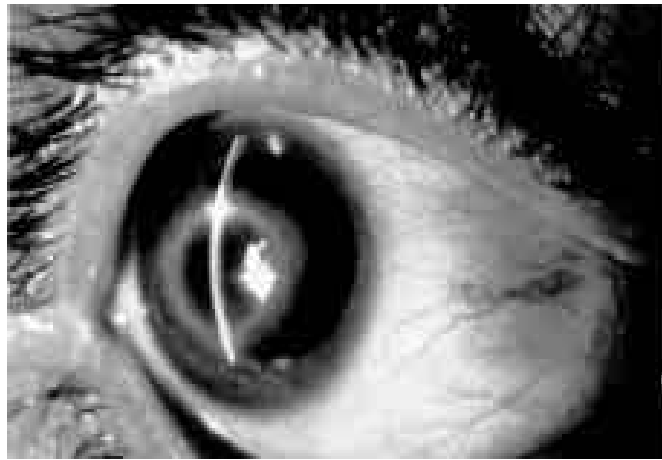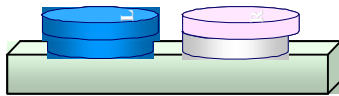


Health Effects Support Document for *Acanthamoeba*



Health Effects Support Document for *Acanthamoeba*

U.S. Environmental Protection Agency
Office of Water (4304T)
Health and Ecological Criteria Division
Washington, DC 20460

www.epa.gov/safewater/ccl/pdf/acanthamoeba.pdf

EPA-822-R-03-012
May 2003

FOREWORD

The Safe Drinking Water Act (SDWA), as amended in 1996, requires the Administrator of the Environmental Protection Agency to establish a list of contaminants to aid the agency in regulatory priority setting for the drinking water program. In addition, SDWA requires EPA to make regulatory determinations for no fewer than five contaminants by August 2001. The criteria used to determine whether or not to regulate a chemical on the CCL are the following:

- The contaminant may have an adverse effect on the health of persons.
- The contaminant is known to occur, or there is a substantial likelihood that the contaminant will occur, in public water systems with a frequency and at levels of public health concern.
- In the sole judgment of the administrator, regulation of such contaminant presents a meaningful opportunity for health risk reduction for persons served by public water systems.

The Agency's findings for all three criteria are used in making a determination to regulate a contaminant. The Agency may determine that there is no need for regulation when a contaminant fails to meet one of the criteria. The decision not to regulate is considered a final agency action and is subject to judicial review.

This document provides the health effects basis for the regulatory determination for *Acanthamoeba*.

ACKNOWLEDGMENTS

The Health Effects Support Document for *Acanthamoeba*, EPA-822-R-03-012, was written by:

Nena Nwachuku, Ph.D., Office of Science and Technology, Office of Water, and Charles P. Gerba, Ph.D., University of Arizona, Tucson, Arizona. The Lead U.S. EPA Scientist on *Acanthamoeba* is Nena Nwachuku, Ph.D., Health and Ecological Criteria Division, Office of Science and Technology, Office of Water.

Peer review comments on two earlier versions of this document were provided by the following internal EPA peer reviewers:

Rita Schoeny, Ph.D. (Office of Science and Technology, Office of Water); Paul S. Berger, Ph.D.; Guy Carruthers; David Soderberg; James Sinclair, Ph.D. (Office of Ground Water and Drinking Water, Office of Water); and Al Dufour, Ph.D. (Office of Research and Development).

This final version also addresses comments by six external expert reviewers:

Govinda Visvesvara, Ph.D., and Hercules Moura, Ph.D., Centers For Disease Control and Prevention; A. Julio Martinez, M.D., University of Pittsburgh; Walter Jakubowski, WaltJay Consulting; Hassan Alizadeh, Ph.D., University of Texas Medical Center; and Jerry Niederkorn, Ph.D., University of Texas Medical Center.

Management support was provided by Geoffrey Grubbs, Director, Office of Science and Technology, Office of Water, U.S. EPA.

TABLE OF CONTENTS

LIST OF TABLES v

LIST OF FIGURES vi

GLOSSARY OF TERMS vii

1.0 EXECUTIVE SUMMARY 1-1

2.0 INTRODUCTION 2-1

3.0 GENERAL INFORMATION AND PROPERTIES 3-1

 3.1 History and Taxonomy 3-1

 3.2 General Characteristics 3-2

 3.3 Methods of Identification 3-5

 3.4 Cultivation 3-5

 3.5 Significance of Endosymbiosis 3-5

4.0 OCCURRENCE 4-1

 4.1 Water 4-2

 4.1.1 Surface Waters 4-2

 4.1.1.1 Freshwaters 4-2

 4.1.1.2 Seawater 4-2

 4.1.2 Tapwater and Bottled Water 4-3

 4.1.3 Swimming Pools and Spas 4-4

 4.1.4 Sewage and Biosolids 4-4

 4.2 Animal Wastes 4-5

 4.3 Air, Dust and Soil 4-5

 4.4 Summary 4-5

5.0 HEALTH EFFECTS 5-1

 5.1 Eye Infections (*Acanthamoebic Keratitis*) 5-3

 5.1.1 Symptoms of *Acanthamoeba Keratitis* 5-5

 5.1.2 Diagnosis of *Acanthamoeba Keratitis* 5-6

 5.1.3 Identification Procedures 5-6

 5.1.4 Treatment of *Acanthamoebic Keratitis* 5-6

 5.1.5 Incidence of *Acanthamoeba Keratitis* 5-7

 5.1.6 Pathogenicity 5-8

 5.1.7 Immunity 5-9

5.2 Granulomatous Amoebic Encephalitis	5-10
5.2.1 Diagnosis and Treatment of GAE	5-12
5.2.2 Incidence of GAE	5-12
5.2.3 Pathogenesis and Immunity	5-13
5.3 GAE in Domestic Animals and Wildlife	5-13
5.4 Other Infections caused by <i>Acanthamoeba</i>	5-13
5.5 Immunocompromised Individuals	5-14
5.6 Incidence to Children	5-14
5.7 Effect of Endosymbiosis on Virulence	5-15
6.0 HEALTH EFFECTS	6-1
6.1 The Organism and its Occurrence (Exposure)	6-1
6.2 Epidemiological Evidence for <i>Acanthamoeba</i> Keratitis Transmission by Tapwater	6-1
6.3 Resistance to Drinking Water Treatment and Disinfection	6-2
6.4 Dose Response	6-3
6.5 Risk Characterization	6-3
7.0 ASSOCIATION OF CONTACT LENSES WITH ACANTHAMOEEBIC KERATITIS ...	7-1
7.1 Types of Contact Lenses	7-1
7.2 Demographics of Contact Lens Use	7-2
7.3 Risk Factors	7-3
7.4 Contact Lens Disinfection	7-5
7.4.1 Studies of Lens Disinfection	7-5
7.4.2 Hydrogen Peroxide	7-6
7.4.3 Multi-Purpose Solutions	7-7
8.0 DATA GAPS	8-1
9.0 REFERENCES	9-1

LIST OF TABLES

Table 2.1	Major Waterborne/Water-based Pathogenic Protozoa	2-1
Table 3.1	Currently Identified Species of <i>Acanthamoeba</i>	3-1
Table 3.2	<i>Acanthamoeba</i> Species Classification	3-2
Table 3.3	Bacterial Endosymbionts of <i>Acanthamoeba</i>	3-6
Table 4.1	Occurrence of <i>Acanthamoeba</i>	4-1
Table 5.1	Comparison of Clinical and Pathological Features of Granulomatous Amoebic Encephalitis (GAE) and <i>Acanthamoeba</i> Keratitis (AK)	5-1
Table 5.2	Characteristics and Symptoms of Patients with <i>Acanthamoeba</i> Keratitis	5-3
Table 5.3	Worldwide Incidence of <i>Acanthamoeba</i> Keratitis	5-8
Table 6.1	Human Infection Caused by Species of <i>Acanthamoeba</i>	6-2
Table 6.2	Mechanisms involved in <i>Acanthamoeba</i> Keratitis	6-4
Table 7.1	History of Contact Lens Development	7-1
Table 7.2	Types of Contact Lenses	7-2
Table 7.3	Wearers and Types of Contact Lenses	7-3
Table 7.4	Age Distribution of Contact Lens Wearers in the United States	7-3
Table 7.5	Risk Factors Associated with Acanthamoebic Keratitis	7-4
Table 7.6	Types of Contact Lenses Associated with Acanthamoebic Keratitis	7-4
Table 7.7	Risk Factors for Acanthamoebic Keratitis in Contact Lens Wearers	7-5

LIST OF FIGURES

Figure 3.1 Life Cycle of *Acanthamoeba* Species 3-3

Figure 3.2 *Acanthamoeba* trophozoite. 3-4

Figure 3.3 Cysts of *Acanthamoeba*. 3-4

Figure 3.4 Significance of Endosymbiosis to Waterborne Disease Transmission 3-7

Figure 5.1 Life Cycle of *Acanthamoeba* spp. and Human Infection 5-2

Figure 5.2 Slit lamp view showing a paracentral complete ring infiltrate of the cornea 5-5

Figure 5.3 Normal Eye 5-5

Figure 5.4 Granulomatous Amoebic Encephalitis (GAE) 5-11

Figure 6.1 Eye Trauma and Contact Lenses as Determinants of Susceptibility to
Acanthamoeba Keratitis 6-5

GLOSSARY OF TERMS

Amphizoic amoeba	Amoeba able to live both free in nature and as pathogens in a host
Anterior uveitis	Inflammation of the iris and ciliary body
Axenic	Grown in the absence of other microorganisms
Cytopathogenic effects	Alteration of the appearance of animal cells in culture due to the growth of pathogenic microorganisms
Confocal microscopy	Microscopy using a laser-scanning fluorescent microscope which gives a digital two-dimensional signal that is reconstructed into a three dimensional image
Cornea	The clear, transparent anterior portion of the fibrous coat of the eye
Endocyst	The innermost cellulose-containing layer of the <i>Acanthamoeba</i> cyst. It may be stellate, polygonal, oval, triangular, or round.
Endosymbiosis	One organism living within the other in a mutually beneficial relationship
Epithelium	The layer of cells forming the epidermis of the skin and the surface layer of mucous and serous membranes
Exocyst	The wrinkled proteinaceous outer layer of the <i>Acanthamoeba</i> cyst
Free-living	Replicate in the environment and do not require a host
Granulomatous amoebic encephalitis	Subacute opportunistic infection caused by <i>Acanthamoeba</i> spp. It spreads from lung or skin lesions to the central nervous system, resulting in neurologic deficits that progress to meningoencephalitis and death
Hematogenous spread	Spread through the blood
Keratitis	Inflammation of the cornea
IgA	The predominant antibody class present in secretions
IgG	The predominant antibody present in human serum

Macrophage	Cells found in the body having the ability to engulf or phagocytose particulate substances (e.g. bacteria)
Meningoencephalitis	Inflammation of the brain and meninges
Nodular scleritis	A small aggregation of cells causing inflammation of the sclera
Ocular	Concerning the eye or vision
Phagocytosis	Ingestion (engulfment) and digestion of bacteria
Ring infiltrate	Insoluble complexes formed by soluble antigens and antibodies, that can be visualized as localized rings in the corneal stroma. Diagnostic of free-living amebic keratitis.
Sclera	A tough, white, fibrous tissue that covers the so-called white of the eye, extending from the optic nerve to the cornea
Scleritis	Superficial and deep inflammation of the sclera
Stroma	Foundation supporting tissues of an organ
Stromal	Concerning or resembling the stroma of an organ
Subacute	Between acute and chronic
Uvea	The second vascular coat of the eye, lying immediately beneath the sclera. It consists of iris, ciliary body, and choroid.

1.0 EXECUTIVE SUMMARY

The Safe Drinking Water Act, as amended in 1996, requires the U.S. Environmental Protection Agency (EPA) to publish a Drinking Water Contaminant Candidate List (CCL). During the development of the first draft list in 1996, EPA obtained input from stakeholders including an international panel of expert microbiologists and the Science Advisory Board. The expert microbiologists' panel recommended that EPA issue a public health guidance for controlling *Acanthamoeba* for contact lens wearers. *Acanthamoeba* spp. are protozoan that are common in water and soil and have been associated with inflammation of the human cornea usually in contact lens wearers and chronic encephalitis in immune deficient individuals. The organism is transmitted by contact of the eye or possibly other body surfaces with contaminated water, air or soil. There is no evidence that it is transmitted by ingestion. EPA has developed this document to review the health effects of *Acanthamoeba* and the significance of water in its transmission. A guidance document providing recommendations for control of *Acanthamoeba* will follow. The document is organized into nine chapters and it includes *Acanthamoeba* history and taxonomy, occurrence and health effects, risk factors associated with *Acanthamoeba*, exposure particularly with contact lens users and infection prevention.

Acanthamoeba spp. are protozoa which are widespread in the environment. However, only a few species are capable of causing disease in humans. *Acanthamoeba* are capable of causing eye infections in persons who wear contact lenses or experience eye trauma. It is also capable of causing granulomatous amoebic encephalitis in immune deficient individuals. *Acanthamoeba* that cause disease are also “free-living” i.e. they can reproduce in the environment without infecting a host. Those capable of causing disease are referred to as amphizoic amoeba because of their ability to live both free in nature and as pathogens in a host. *Acanthamoeba* has two stages in its life cycle (cyst and trophozoite). The cyst is the environmentally resistant stage and can survive in the environment for many years. *Acanthamoeba* feed on bacteria, fungi, other protozoa, and cyanobacteria. They are easily grown on non-nutrient agar plates seeded with *Escherichia coli* or *Klebsiella pneumoniae*.

The genus *Acanthamoeba* consists of as many as 20 species classified in three groups based on cyst morphology. Several species of *Acanthamoeba* are known to cause infections in humans. They include *A. astronyxis*, *A. castellanii*, *A. culbertsoni*, *A. divionensis*, *A. griffini*, *A. healyi*, *A. rhyodes*, *A. hatchetti*, *A. palestinensis* and *A. polyphaga*. Contaminated recreational and tap water have been implicated as sources of exposure, especially for those species causing infections of the eye. No studies are available on *Acanthamoeba* spp. in drinking water in the United States. *Acanthamoeba* are abundant in the environment, and can be found in tap water, seawater (frequently near sewage disposal sites and outfall), air, soil, dust, vegetables, and animal wastes. Residential and public pools and spas have been documented as frequent sources of the amoebae which can survive pool and spa disinfection procedures because of their resistant cyst stages. Eye wash stations have also been shown to be reservoirs for the amoebae.

Two types of illnesses are most commonly associated with *Acanthamoeba*. These are *Acanthamoeba* keratitis and granulomatous amoebic encephalitis (GAE). Keratitis occurs primarily in healthy individuals who wear contact lenses or have corneal trauma and GAE occurs primarily in immune deficient individuals. *Acanthamoeba* keratitis is characterized by severe ocular pain, a complete or partial paracentral stromal ring infiltrate, recurrent corneal breakdown of the epithelium, and corneal lesions. While positive diagnosis of acanthamoebic keratitis can be made by *in vivo* confocal microscopy, diagnostic tests usually rely on demonstrating amoebae on corneal scrapings or biopsy material, in which cysts and trophozoites can be visualized with a number of different stains. More recently, molecular techniques such as polymerase chain reaction are becoming part of the diagnostic tools for *Acanthamoeba*.

Risk of acanthamoebic eye infection is associated with eye trauma (physical injury to the eye) or wearing of contact lenses in conjunction with exposure to water containing *Acanthamoeba* such as tapwater, hot tubs, natural springs, bottled water, and non-sterile waters used to store contact lenses. Reports indicate that 85% of cases are associated with individuals who wear contact lenses. The pathogenic potential of *Acanthamoeba* appears to be related to certain strains with an ability to adhere to the cornea and the ability of the host to produce IgA antibodies in the tears.

Contact lenses are medical devices regulated by the Food and Drug Administration (FDA) under the Safe Medical Devices Act of 1990. The FDA provides comprehensive directions for manufacturers of contact lens care products. It has been estimated that 34 million people in the United States, and 71 million people globally wear contact lens. Every individual who wears contact lenses can be infected with *Acanthamoeba* spp. when proper lens care and use of proper procedures for lens care products are not adhered to. There are various types of contact lenses. They are the daily-wear soft lenses, daily-wear disposable soft lenses, extended wear soft lenses, extended wear disposable soft lenses, rigid gas permeable lenses, colored soft contact lenses, and the theatrical or special effects lenses. Of the 34 million people in the United States who wear contact lenses, 80% of them wear soft contact lenses, 64% are female and 36% are male. The approximate percentage of children below the age of 17 who wear soft contact lenses is 10%. As contact lens care became easier and more convenient, people of all ages from as young as 8 years old to over 60 have been issued prescriptions to wear them. Colored contact lenses, which are often worn for cosmetic purposes, have become very popular particularly within the teen population. Teenagers frequently trade, borrow, and swap lenses. This behavior in the teen population has also added to the problem of *Acanthamoeba* keratitis since good hygiene may not be practiced. Treatment for *Acanthamoeba* keratitis includes various combinations of propamidine isethionate (Brolene), dibromopropamidine ointment, neomycin sulfate-polymixin B sulfate-gramicidin, oral itraconazole, topical miconazole, polyhexamethylene biguanide (PHMB), and topical clotrimazole.

Options for lens disinfection include chlorohexidine, benzalkonium chloride, and hydrogen peroxide. Of these, hydrogen peroxide is the most effective chemical disinfectant against bacteria

and *Acanthamoeba*, including trophozoites and cysts. Chlorine is not considered effective. Multi-purpose solutions have been produced to clean and store lenses with a single solution without the need for neutralization of the disinfectant before lens use. Multi-purpose solutions provide the easiest technique for the lens wearer to clean and disinfect the lens and better compliance results have been demonstrated. Multi-purpose solutions contain a detergent with a polyquaternium or polyhexamethylene biguanide (PHMB), in a buffered solution.

Acanthamoeba keratitis is not a reportable disease in the United States so the true incidence is not known. Published work suggests an incidence of 0.58 to 0.71 cases/1,000,000 in the general population, and 1.65 to 2.01/10⁶ among contact lens wearers. One study in the United Kingdom reported an incidence of 149/10⁶ among the general population. In contrast, the incidence of all causes of microbial keratitis (largely bacterial) is about 400/10⁶ among contact lens wearers. Worldwide, the incidence of microbial keratitis has been reported to range from 1.1 to 2,000/10⁶ among contact lens wearers. Difficulties in the diagnosis of *Acanthamoeba* keratitis probably leads to an underestimation of the true number of cases.

Molecular-based investigations have established domestic tapwater as a proven source of *Acanthamoeba* infection in lens wearers. The organisms have been isolated from household taps and probably feed on the microbial biofilm within the distribution system. An epidemiological study in the midwestern United States suggested that an epidemic of presumed *Acanthamoeba* infection was associated with municipal water supplies subjected to flooding during 1993-1994. The incidence of *Acanthamoeba* was ten times greater (1.30 vs. 14.3 cases/10⁶) in areas affected by flooding. The incidence was also significantly lower if the home was supplied with tapwater from a private well. Studies suggest that the risk of *Acanthamoeba* keratitis may be related to concentrations of the organism present in surface waters and tapwater.

Granulomatous amoebic encephalitis (GAE) caused by *Acanthamoeba* is the second major infection associated with *Acanthamoeba*. GAE is now recognized as a disease occurring most often in people with poor immune systems or other debilitating health problems. Predisposing factors include chemotherapy, dialysis, diabetes, treatment with steroids, smoking, or acquired immunodeficiency syndrome. The symptoms of GAE during the initial stage of the disease are indistinguishable from bacterial and viral meningitis. The amoeba is believed to enter the bloodstream, probably via the nose, lungs, or breaks in the skin following injury or trauma. Successful treatment is rare. Pentamidine, propamidine, miconazole, ketoconazole, sulfadiazine, itraconazole, fluconazole, and 5-fluorocytosine may be effective in treating GAE, and efforts to find at least a partially successful treatment are in progress.

The global incidence of recorded GAE cases due to *Acanthamoeba* was 120 cases as of the year 2000, 84 of those occurred in the U.S. and over 50 of the GAE cases were found in AIDS patients. An estimate of *Acanthamoeba* keratitis cases in the U.S. stood at 500 with over 3000 cases worldwide. There is general agreement that both GAE and keratitis have significantly increased in

the last 10 years in the U.S. because of the increase in the use of contact lens wearers of all ages for various reasons including athletic and cosmetic reasons, and the increase in the number of immuno-suppressed individuals.

Other areas of concern with *Acanthamoeba* spp. in drinking water supplies is their symbiotic relationship with waterborne pathogenic bacteria that are able to grow within the cytoplasm of the protozoa. This endosymbiotic relationship with *Legionella*, *Mycobacterium*, and *Pseudomonas* enhances bacterial survival and resistance to disinfectants in water. It also increases the virulence of both organisms, resulting in a greater probability of causing illness. *Acanthamoeba* may play a significant role in the transmission of these bacteria by drinking water. Control of *Acanthamoeba* in distribution systems may be necessary for control of *Legionella* and *Mycobacterium*.

Acanthamoeba cysts are very resistant to inactivation by water disinfectants such as chlorine, iodine, bromine, and ultraviolet light. Doses used in drinking water would not be expected to eliminate them. The cysts of some *Acanthamoeba* cysts, however, are large enough to be removed by filtration. Because of their widespread occurrence in the environment, contamination of household taps, where bacteria upon which they feed are common in the biofilm, their presence would not be unexpected. Concentrations in distribution systems probably depend upon the concentration of heterotrophic bacteria.

While it is clear that a relationship exists between *Acanthamoeba* in water and keratitis, the role of tapwater is not clearly understood. One study suggests that municipal supplies which may have become contaminated enhanced the risk of presumed *Acanthamoeba* keratitis. Additional information on dose needed for infection and quantitative data on occurrence in drinking water supplies would help to better understand the potential risks to contact lens wearers and the general public. The incidence of recognized *Acanthamoeba* keratitis is around 1-2/10⁶. The highest incidence in the U.S., which may have been linked to flooding and the use of municipal water supplies, was 14/10⁶. Even if all the cases of *Acanthamoeba* were associated with tapwater this would be less than the 1:10,000 risk of infection per year that EPA has set as the goal for surface water supplies.

The risk of keratitis is clearly greater for contact lens wearers. If consumers follow contact lens manufacturers' instructions and lens care product instructions for storage and rinsing of lenses, keratitis would be greatly reduced. Proper contact lens care and disinfection are essential for preventing infection by *Acanthamoeba*.

A significant data gap is the absence of information on the occurrence of *Acanthamoeba* spp. in tapwater in the United States. Information on the concentration of *Acanthamoeba* spp., virulence, and type of water treatment would improve the risk assessment process for drinking water. Dose response data could be developed in animals to aid in prediction of the probability of infection from exposure.

2.0 INTRODUCTION

Acanthamoeba is a protozoan genus. Protozoa are unicellular eukaryotic animals. While protozoa are widespread in the environment, only a few are capable of causing disease in humans. Several of the pathogenic protozoa are transmitted by water, including *Giardia lamblia*, *Cryptosporidium* spp., *Naegleria fowleri* and certain *Acanthamoeba* spp (Table 2.1).

Acanthamoeba are free-living amoebae which have no defined shape. They move by pseudopods, extensions of the cell membrane into which the cytoplasm moves. They normally live in soil, fresh water, brackish water, sewage, and biosolids, feeding on bacteria, and multiplying in their environmental niche as free living organisms. They are capable of causing infections of the human skin, lungs, eye and brain, and can feed on human tissue. Because of their ability to live both free in nature and as pathogens in a host, they are also called amphizoic amoeba. This is in contrast to the *Giardia* and *Cryptosporidium* which do not replicate in the environment (Table 2.1). These waterborne pathogenic protozoa are transmitted only by ingestion and replicate only within the host.

The genus *Acanthamoeba* consists of as many as 20 species classified in three groups based on their morphology (Table 3.2). Unlike *Naegleria fowleri*, the most important species of *Naegleria* that causes human disease, several species of *Acanthamoeba* are known to cause infections in humans. They include *A. astronyxis*, *A. castellanii*, *A. culbertsoni*, *A. divionensis*, *A. healyi*, *A. rhyodes*, *A. hatchetti*, *A. palestinensis* and *A. polyphaga*. Exposure to contaminated recreational and tapwater has been implicated as a source of exposure, especially for those species causing infections of the eye.

Table 2.1 Waterborne/Water-based Pathogenic Protozoa

Type	Genus/species	Disease/Symptoms
Amoeboid	<i>Acanthamoeba</i>	eye infection (keratitis), brain infection(meningo-encephalitis)
	<i>Naegleria</i>	brain infection(meningo-encephalitis)
	<i>Entamoeba histolytica</i>	amoebic diarrhea (liver abscess)
Flagellate	<i>Giardia lamblia</i>	diarrhea
Apicomplexan	<i>Toxoplasma gondii</i>	fever, loss of fetus
	<i>Cryptosporidium</i>	diarrhea
	<i>Cyclospora</i>	diarrhea
	<i>cayetanesis</i>	

3.0 GENERAL INFORMATION AND PROPERTIES

3.1 History and Taxonomy

Prior to the 1950's, amoebae such as *Entamoeba histolytica* were classified as parasitic (requiring a host for replication), while species of *Acanthamoeba* were viewed as free-living (replicate in the environment). However, Jahnes *et al.* (1957) found that an unidentified species of *Acanthamoeba* could cause cytopathogenic effects in monkey kidney cell cultures, and Culbertson *et al.*(1958) found that it could cause meningoencephalitis in experimentally infected animals. Results of studies with laboratory animals led to the finding that these free-living amoebae had caused fatal meningitis in several patients. The term “free-living pathogenic amoebae”, or PFLA, has been used to describe these opportunistic pathogens. They are now referred to as amphizoic amoeba (Page, 1967).

Taxonomy of *Acanthamoeba* is a contentious area. Those species now known as *Acanthamoeba* were previously placed in the genus *Hartmanella*, but in 1967 they were definitely classified as a separate genus by Page (1967). Pussard and Pons (1977) later proposed a classification based mainly on cyst morphology that identified 18 species (Table 3.1). The species were classified into three morphologic groups (Table 3.2). Group I has large cysts with rounded outer walls (ectocysts) that are clearly separated from the inner walls (endocysts). The inner and outer walls are joined, forming a star-shaped structure. Group II cysts are smaller, with variable endocyst shapes. Group III cysts are smaller than Group II cysts, with poorly separated walls. The major human pathogens belong to Group II, although *A. culbertsoni*, from Group III, is also a recognized pathogen.

Table 3.1 Currently Identified Species of *Acanthamoeba*

Species	Species
<i>A. astronyxis</i>	<i>A. mauritaniensis</i>
<i>A. castellanii</i>	<i>A. palestinensis</i>
<i>A. comandoni</i>	<i>A. paradivionensis</i>
<i>A. culbertsoni</i>	<i>A. pearcei</i>
<i>A. divionensis</i>	<i>A. polyphaga</i>
<i>A. echinulata</i>	<i>A. quina</i>
<i>A. gigantea</i>	<i>A. rhysodes</i>
<i>A. griffini</i>	<i>A. royreba</i>
<i>A. hatchetti</i>	<i>A. stevensoni</i>
<i>A. healyi</i>	<i>A. terricola</i>
<i>A. jacobsi</i>	<i>A. triangularis</i>
<i>A. lenticulata</i>	<i>A. tubiashi</i>
<i>A. lugdunensis</i>	

Table 3.2 *Acanthamoeba* Species Classification (Pussard and Pons, 1977)

Group I	Group II	Group III
<i>A. astronyxis</i>	<i>A. castellani</i>	<i>A. palastinensis</i>
<i>A. comandoni</i>	<i>A. mauritaniensis</i>	<i>A. culbertsoni</i>
<i>A. echinulata</i>	<i>A. polyphaga</i>	<i>A. lenticulata</i>
	<i>A. lugdunensis</i>	<i>A. pustulosa</i>
	<i>A. quina</i>	<i>A. royreba</i>
	<i>A. rhysodes</i>	
	<i>A. divionensis</i>	
	<i>A. paradivionensis</i>	
	<i>A. griffini</i>	
	<i>A. triangularis</i>	

3.2 General Characteristics

Acanthamoeba has two stages in its life cycle: the trophozoite and the cyst (Figure 3.1). *Acanthamoeba* trophozoites measure 15 to 45 µm and are characterized by the presence of fine, tapering, spine-like projections from the surface of the body, called acanthopodia. The acanthopodia can be periodically protruded and retracted (Figure 3.2). The trophozoites usually have one nucleus with a large, dense nucleolus. *Acanthamoeba* divide by conventional mitosis, in which the nucleolus and the nuclear membrane disappear during cell division. Numerous mitochondria, ribosomes, lysosomes, and vacuoles are present within the cytoplasm. The trophozoite feeds on bacteria by engulfing them (phagocytosis). Under adverse environmental conditions a dormant cyst is formed, which is resistant to desiccation, temperature extremes and disinfectants. The cyst is slightly smaller than the trophozoite (15-28 µm in length) (Figure 3.3). It has one nucleus and is double-walled, with a wrinkled proteinaceous outer ectocyst and an inner cellulose-containing endocyst. The inner endocyst may be stellate, polygonal, oval, triangular or round. Pores or ostioles are present at the point of contact between the ectocyst and endocyst (Figure 3.3).

The cyst may remain viable for many years and when it is exposed to a food source, it again assumes the trophozoite form. It is not understood how the cyst recognizes a food source. It will readily excyst in the presence of both liquid nutrients and bacteria.

Acanthamoeba are carriers of intracellular bacteria, especially *Legionella* species, which have the ability to reproduce within the trophozoite. It has been proposed that this may be of importance in the persistence and spread of these organisms in the environment (King *et al.*, 1988).

Figure 3.1 Life Cycle of *Acanthamoeba* Species

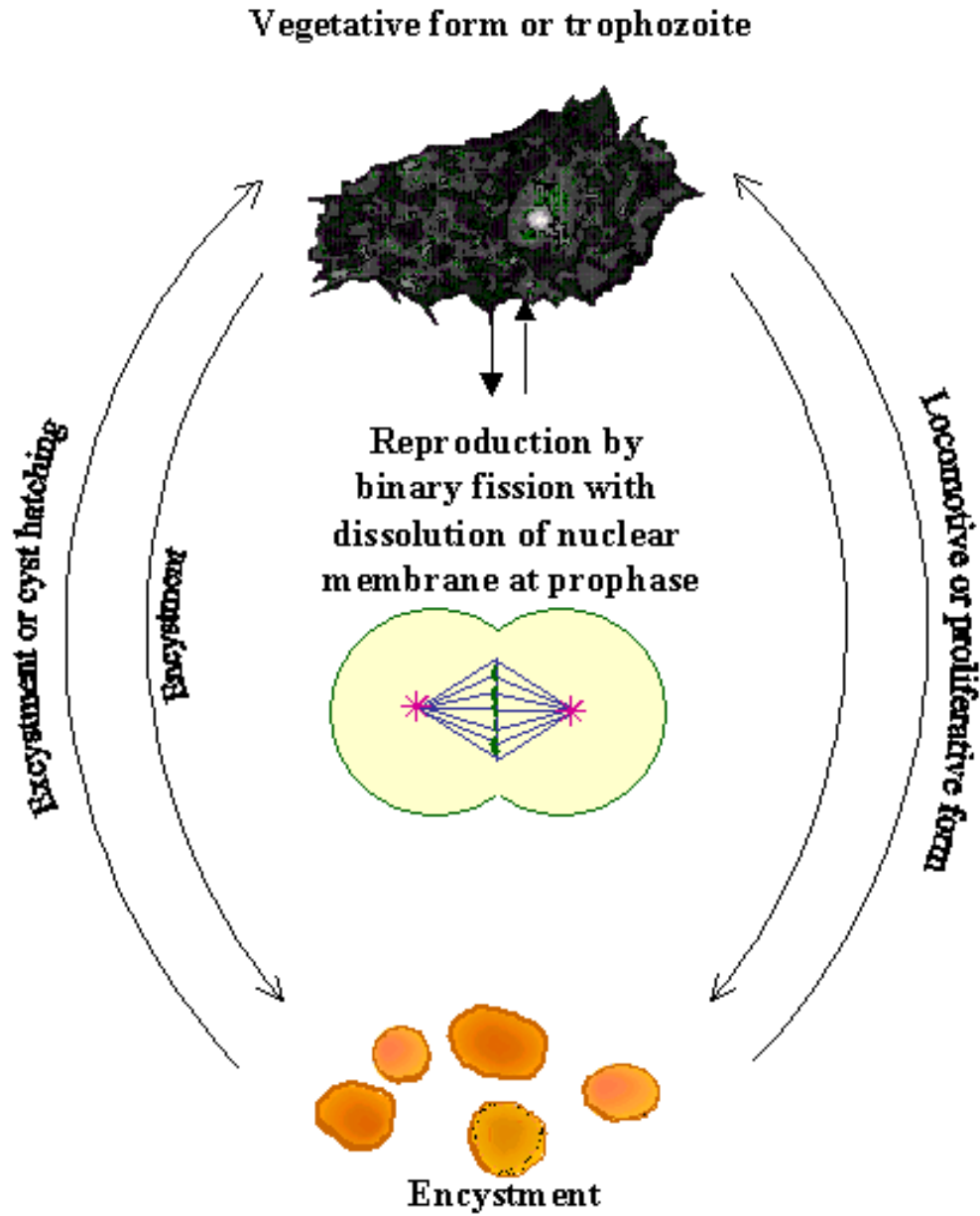


Figure 3.2 *Acanthamoeba* Trophozoite (amebic stage). Note the characteristic spine-like acanthopodia. (Visvesvara, 1987)

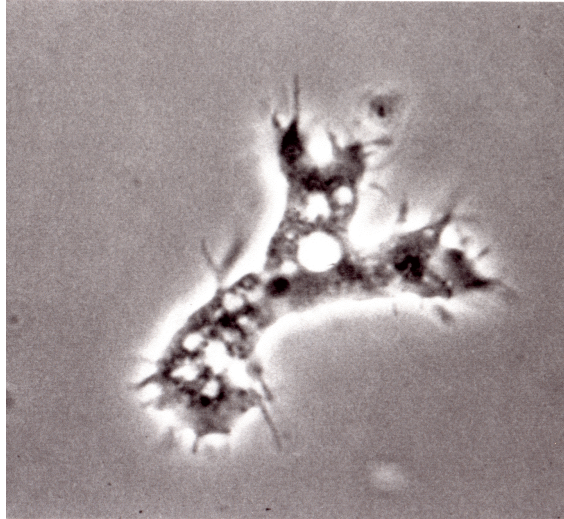
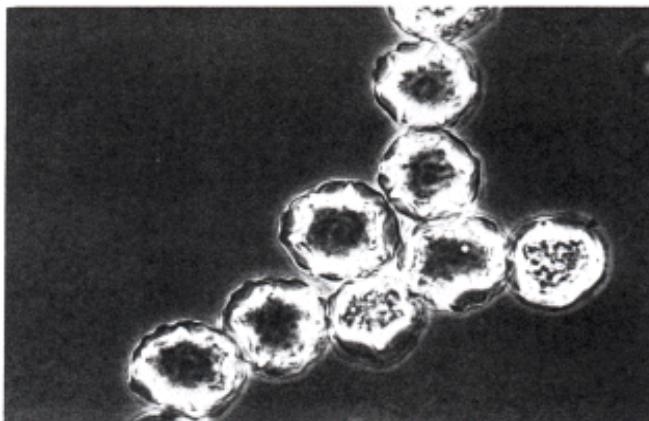


Figure 3.3 Cysts of *Acanthamoeba*. Note the characteristic double wall with an outerwrinkled ectocyst and an inner polygonal endocyst (Visvesvara, unpublished)



3.3 Methods of Identification

The identification of individual species of *Acanthamoeba* is based on morphological observations, but recent taxonomic studies have employed isoenzyme (de Jonckheere, 1987) or mitochondrial DNA restriction endonuclease analysis in an attempt to form a classification system. A study of mitochondrial DNA has produced comparable results. In the first study, 33 strains, of which 30 were corneal isolates, were separated into ten groups according to restriction length pattern polymorphism.

3.4 Cultivation

Acanthamoeba are easily grown on non-nutrient agar plates seeded with *Escherichia coli* or *Klebsiella pneumoniae* (Kilvington *et al.*, 1990; Visvesara *et al.*, 1975). One of the more common methods is to smear or streak a suitable bacterial food organism such as *Escherichia coli* or *Klebsiella pneumoniae* over the agar surface, seal the plates with tape, invert them and incubate them in boxes lined with wet paper towels to maintain humidity. *Acanthamoeba* will migrate across the plate using bacteria as a food source. Overproliferation of bacteria is prevented by the non-nutrient agar. With incubation at 32°C, the migration tracks of the amoebae are usually easily visible within 48 hours, but occasionally longer incubation (up to two weeks) is needed (Illingworth and Cook, 1998).

Formulations for several complex liquid axenic (bacteria-free) media may be found in a publication by the American Type Culture Collection (Nerad, 1993). Since some species of amphizoic amoeba grow at mammalian body temperatures, many labs incubate replicate cultures at room temperature, 37°C to 45°C, or higher.

3.5 Significance of Endosymbiosis

Acanthamoeba feeds on bacteria in the environment trapping them within its cytoplasm, a process known as phagocytosis. Phagocytosed bacteria are usually killed and digested by the amoebae, however, some species of bacteria may grow and reproduce within the cytoplasm and become symbionts. Symbiotic relationships are beneficial to both organisms. When the bacteria have adapted to the intercellular environment of the protozoan host, the event is referred to as endosymbiosis. Both the survival and virulence of both organisms may be enhanced by this relationship (see Section 5.7). Rowbotham (1980) first reported the association of the amoebae *Naegleria* and *Acanthamoeba* with the symbiont *Legionella pneumophila*, the causative agent of Legionnaire's disease. Several species of free-living amoeba have been shown to support the growth of legionellas (Fields, 1993) and environmental growth of legionellas in the absence of protozoa has not been documented. It is thought that the protozoa are the primary means of proliferation of these bacteria under natural conditions (Fields *et al.*, 1989; Hay *et al.*, 1995). This endosymbiotic relationship can modify the virulence of *Legionella* (Dowling *et al.*, 1992). It may also be involved in the observed phenomenon that *L. pneumophila* can be viable but non-detectable by cultivation on agar-based systems (Connor *et al.*, 1993). Hay and Seal (1994b)

have proposed that the latter observation may have profound implications with regard to surveillance of water systems for *Legionella*, especially with prevention of outbreaks of nosocomial Legionnaire's disease.

Various waterborne pathogens have been shown to develop an endosymbiotic relationship. The spectrum of pathogens able to survive and multiply to various degrees within *Acanthamoeba* is given in Table 3.3. For all of the organisms, *Acanthamoeba* are potential reservoirs and vectors, due in part to their ubiquity in the environment, their resistant cyst stages, and their potential to grow in water supplies, cooling, humidification systems, and recreational waters.

Endosymbiosis has also been shown to protect *Legionella* against disinfection (Kilvington and Price, 1990), and enhance the ability of both the bacteria and protozoa to cause disease (see Section 5.7). Thus, the presence of *Acanthamoeba* in drinking water distribution systems may not only add to the survival of other waterborne pathogens, but this relationship may enhance their virulence (Figure 3.4).

Table 3.3 Bacterial Endosymbionts* of *Acanthamoeba*

Legionella pneumophila

Mycobacterium avium

Burkholderia picketti

Vibrio cholerae

Francisella tularensis

Chlamydia pneumoniae

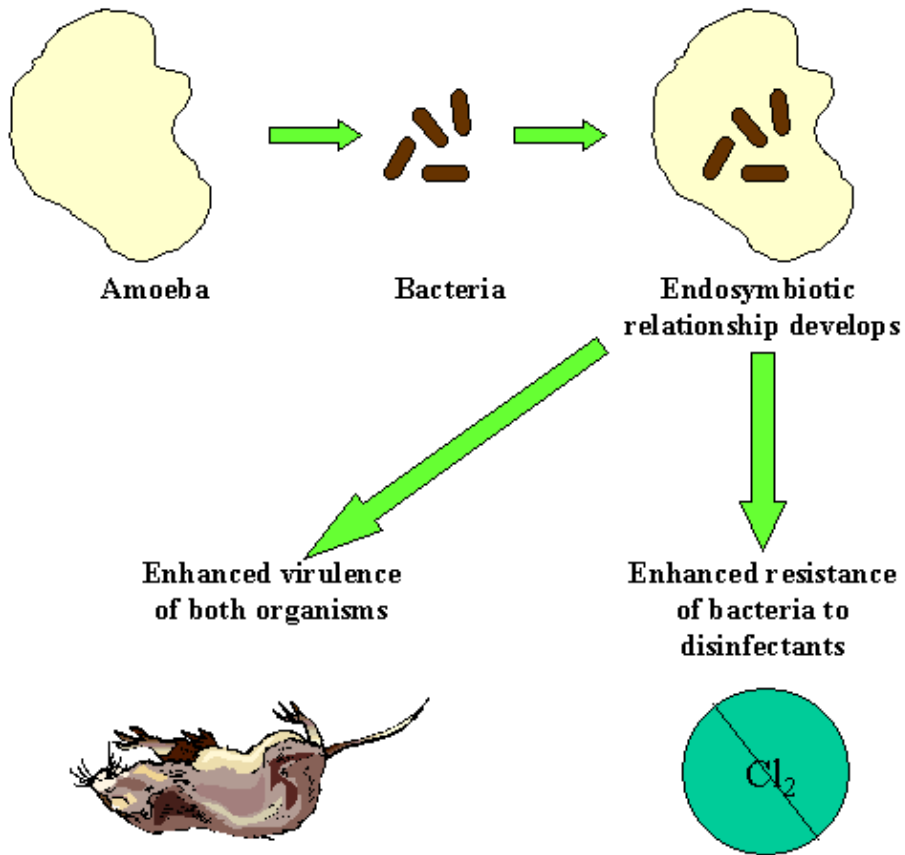
Rickettsiales

Listeria monocytogenes

Fritsche et al., 1999; Ly and Miller, 1990

*live within the *Acanthamoeba*

Figure 3.4 Significance of Endosymbiosis to Waterborne Disease Transmission



4.0 OCCURRENCE

Acanthamoeba are abundant in the environment and have been isolated from tapwater, seawater, air, soil, dust, and vegetables (Table 4.1). They feed on bacteria, fungi, other protozoa, and cyanobacteria (blue-green algae) (Rodriguez-Zaragoza, 1994). They are found in greatest numbers where other microorganisms are most numerous.

Table 4.1 Occurrence of *Acanthamoeba*

Source	Reference
Water fountains	Crespo <i>et al.</i> , 1990
Tap water (Mexico)	Rivera <i>et al.</i> , 1979
Bottled water (Mexico)	Rivera <i>et al.</i> , 1981
Hospital tap water	Rohr <i>et al.</i> , 1998
Eyewash stations	Tyndall <i>et al.</i> , 1987
Freshwater ponds	John and Howard, 1995
Thermal water	DeJonckheere, 1979, Dive <i>et al.</i> , 1982
Well water	Jones <i>et al.</i> , 1975
Physiotherapy tubs	Penas-Ares <i>et al.</i> , 1994
Aquaria	DeJonckheere, 1979
Municipal sewage	Singh and Das, 1972
Ocean sewage dump site	Sawyer <i>et al.</i> , 1982
House dust	Yamaura <i>et al.</i> , 1993
Garden soil	Singh, 1952
Sand box	Yamaura <i>et al.</i> , 1993
Garden vegetables	Rude <i>et al.</i> , 1984
Fish	Taylor, 1977
Air conditioner	Walker <i>et al.</i> , 1986

4.1 Water

4.1.1 Surface Waters

4.1.1.1 Freshwaters

One of the early studies on the numbers of *Acanthamoeba* in a freshwater lake was published by O'Dell (1979). He noted a distinct seasonal variation in populations of *A. polyphaga* ranging from approximately 200/gram (g) to 1,000/g of lake-bottom mud during February through July, and 200/g to 2,100/g during the period of August through January. Peak counts were noted during August and September. *Acanthamoeba castellanii* was also observed in this study, but was recovered only on three occasions and did not exceed a population of 200/g. Detterline & Wilhelm (1991) collected water samples from 59 sites in federally managed recreational waters of the U.S. and recovered temperature-tolerant strains of *Acanthamoeba* from 16 of 31 sites that grew at 37°C. Kyle and Noblet (1987) published a detailed account of amoebae present in a spillway reservoir in South Carolina. The authors studied the lake throughout the course of a year to record seasonal influences on amoeba populations, such as dissolved oxygen, attenuation, and water temperature. Information on amphizoic amoebae from this study showed that in the surface water they ranged from 5 to 10 amoebae /50 milliliters (ml) water in May, and peaked at 98/50 ml in July.

Asiri *et al.* (1990) tested sediments along a transect in the Potomac River ranging from non-tidal waters above Washington, D.C. to tidal waters (brackish) 0.8 m below a municipal sewage treatment plant. They identified seven species of *acanthamoeba*, most of which occurred in the tidal portion of the river near the sewage treatment plant. John and Howard (1995) processed 2,016 samples from ponds in Oklahoma and recovered 34 strains of pathogenic (induced brain damage) amoebae with 35 percent identified as *Acanthamoeba*. They estimated that there was approximately 1 pathogen per 60 samples, and 1 pathogen per 3.4 liters of water. They found the highest percentage of pathogens during spring and fall, while Kyle and Noblet (1987) found summer and fall to be the peak periods.

4.1.1.2 Seawater

Acanthamoeba spp. have been occasionally detected in marine water and sediments. Most studies on *Acanthamoeba* spp. in marine sediments have been carried out in areas where sewage and other wastes have been disposed of at sea (O'Malley *et al.*, 1982; Sawyer *et al.*, 1982). In another study, Sawyer *et al.* (1992) recovered several species of *Acanthamoeba* from sewage-contaminated inshore New York and New Jersey shellfish beds that periodically were closed to

shellfish harvesting. Munson (1993) recovered several species of *Acanthamoeba* from coastal waters of Bermuda, and noted a high frequency of recovery of *Acanthamoeba* spp. near sewage outfalls.

4.1.2 Tapwater and Bottled Water

Acanthamoebae have been detected in tapwater and several studies have documented their occurrence, however, all of these studies have been done in countries other than the United States. Rivera *et al.* (1979) collected 25 one-gallon water samples from faucets in private residences in Mexico. Flagellates were found in 84% of the samples, amoebae in 13% and ciliates in 1.9%. Although found infrequently, *Acanthamoeba astronyxis* and *A. castellanii* were recovered from the same samples. In another study, Hamadto *et al.* (1993) tested 50 tap water samples in Egypt and recovered unidentified species of *Acanthamoeba* from two of them. Michel *et al.* (1998) tested drinking water in a new hospital in Germany and found amoebae in 20 of 37 (54 %) samples; two of sixteen isolates of *Acanthamoeba* were pathogenic to mice. Rohr *et al.* (1998) collected water from 56 hot water taps in hospitals, also in Germany, and found amoebae in 29 (56 %) of them. The authors recovered five genera of cyst-forming amoebae but none of them were species of *Acanthamoeba*. In England, Seal *et al.* (1992) isolated *Acanthamoeba* from five of six bathroom cold water taps supplied by storage tanks and one kitchen cold water tap supplied by the mains. When 41 strains of amoebae were recovered from 49 swab samples collected from moist areas in the hospital, such as walls, floor tiles, and sinks, 22 percent were species of *Acanthamoeba*. In a more recent study in Germany, Michel *et al.* (1998) recovered a species of *Acanthamoeba* from a hospital cold-water tap. In a more recent study in Hong Kong, Houang *et al.* (2001) found that 8% of the homes were colonized with *Acanthamoeba*.

The common occurrence of *Acanthamoeba* in eye wash stations filled with tapwater containing free chlorine (concentration of chlorine was not reported) has been reported in the United States (Bowman *et al.*, 1996). *Acanthamoeba* are able to grow in stagnant water in eye wash stations and regular flushing is required to control their numbers. The presence of free chlorine or other disinfectants was not reported in any of the previous studies.

Rivera *et al.* (1981) tested three popular brands of bottled mineral waters available in local stores in Mexico and identified *Naegleria gruberi*, *Vahlkampfia vahlkampfi*, and *Acanthamoeba astronyxis*. The author did not state how or if the water had received any processing before bottling.

4.1.3 Swimming Pools and Spas

Residential and public pools and spas have been documented as frequent sources of amphizoic amoebae, including *Acanthamoeba*. When amoebae were first identified as a cause of meningitis, Lyons and Kapur (1977) tested water from 30 public pools in New York disinfected with either chlorine or bromine and recovered amoebae from 27 of them. The species were not identified but were referred to as belonging to the “*Hartmannella-Acanthamoeba*” group, a term often used before the two genera were recognized as distinct taxonomic entities. *Acanthamoeba* has been in swimming pools or other bodies of water around the world, including Germany (Janitschke *et al.*, 1980), Mexico (Rivera *et al.*, 1983) and frozen swimming areas in Norway (Brown and Cursons, 1977).

Thermal bathing pools (spas) are also sources for potentially pathogenic amoebae (Martinez, 1985). Brown *et al.* (1983) tested 9 thermal pools in New Zealand and identified temperature tolerant strains of *Acanthamoeba* from 20 percent of them. They set up 88 subsamples from the pools and found *Acanthamoeba* in 5 of them (5.7 percent). Rivera *et al.* (1987) studied three resorts in Mexico that received water flowing from natural springs of thermal water. They recovered 12 strains of *Acanthamoeba* from cultures incubated at 42°C to 45°C. Two strains were identified as *A. castellanii*, one as *A. lugdunensis* and the others as *Acanthamoeba* spp. All were pathogenic to mice. The authors conducted a second study (Rivera *et al.*, 1991) and recovered *A. culbertsoni* and *A. polyphaga* from heated physiotherapy tubs. Penas-Ares *et al.* (1994) tested heated water used to fill 12 spas in Spain. The water was classified as sulphurous, and temperature ranged from 34°C to 64°C. The authors recovered 13 strains of amoebae from 8 of the spas. Four of the 8 spas yielded *A. polyphaga* or *A. lenticulata*, with only *A. polyphaga* found to be pathogenic to mice. The amoebae may survive pool and spa disinfection procedures because of their resistant cyst stages.

4.1.4 Sewage and Biosolids

Daggett (1982) published a description of potentially pathogenic *Acanthamoeba* and *Naegleria* in polluted waters with emphasis on health risks to divers. Singh and Das (1972) studied biosolid samples in Bombay, India and recovered strains of *Acanthamoeba culbertsoni* and *A. rhyodes* that were pathogenic to mice. Bose *et al.* (1990) extended studies on sewage in India to include Calcutta, where they isolated a pathogenic strain of *A. castellanii* and a non-pathogenic strain of *A. astronyxis*.

4.2 Animal Wastes

Bovee *et al.* (1961) tested intestinal contents from reptiles in Florida using the agar plate method and recovered amoebae from 35 of 157 fecal samples. Wilson *et al.* (1967) conducted a follow-up study in Florida and identified cyst-forming genera of amoebae representing *Acanthamoeba* from water and the intestinal contents of snakes and lizards. Jadin *et al.* (1973) carried out an extensive study on wildlife in France and recovered *Acanthamoeba* from the feces of snakes, toads, frogs, ducks, gulls, and muskrats. The study showed that animals largely aquatic in habitat could be sources of *Acanthamoeba* in natural bodies of water. Franke and Mackiewicz (1982) discovered animals that transport *Acanthamoeba* in their feces by culturing *A. polyphaga* from the common shiner, *Notropis cornatus*, and the white sucker, *Catostomus commersoni*, from streams in New York. Simitzis and Chastel (1982) reported finding species of *Acanthamoeba* in feces of small feral mammals in Brittany, Tunisia, and France.

4.3 Air, Dust and Soil

Air is a carrier of dust, dirt, fungal spores, and other forms of particulate matter. During a dust storm in Zaire, Africa, Lawande *et al.* (1979) collected nasal swabs from 50 children ranging in age from 1 month to 10 years and recovered soil amoebae from 12 (24%) of them. Two of the twelve children harbored *A. rhysodes*. Lawande (1979) also exposed open culture plates to the atmosphere for periods of 30 minutes to 4 hours. Amoebae identified as *A. castellanii* and *A. culbertsoni* were recovered as early as 30 minutes after the plates were opened. The study throughout the 4-hour period yielded other species as well, including *A. astronyxis*, *A. palestinensis*, and *A. rhysodes*. Rivera *et al.* (1987) conducted similar studies during the rainy season in Mexico City, Mexico. They recovered *A. astronyxis*, *A. castellanii*, *A. culbertsoni*, and *A. polyphaga* from air. In a second study of air in Mexico, Rivera *et al.* (1991) recovered nine species of *Acanthamoeba*. Air conditioners and cooling towers also contribute moisture and microbial pathogens including *Acanthamoeba* in the atmosphere (Walker *et al.*, 1986; Ma *et al.*, 1990; el Sibae, 1993). Kingston and Warhurst (1969) conducted quantitative studies on the density of *Acanthamoeba* cysts in outdoor air. They recorded values of one cyst per m³ and one cyst of *A. castellanii* per 18.3 m³ of air.

4.4 Summary

Acanthamoeba can be isolated from most aquatic environments, air, and soil. Their concentration in water is related to the number of bacteria upon which they feed. Little quantitative information is available on their concentration in water and their occurrence in distribution systems and tapwater has not been systematically studied in the United States. Recreational exposure may occur because of their presence in swimming pools, hot tubs and surface waters.

They may occur seasonally in greater numbers in the early spring and early fall. The occurrence of *Acanthamoeba* in the environment is summarized in Table 4.1.

5.0 HEALTH EFFECTS

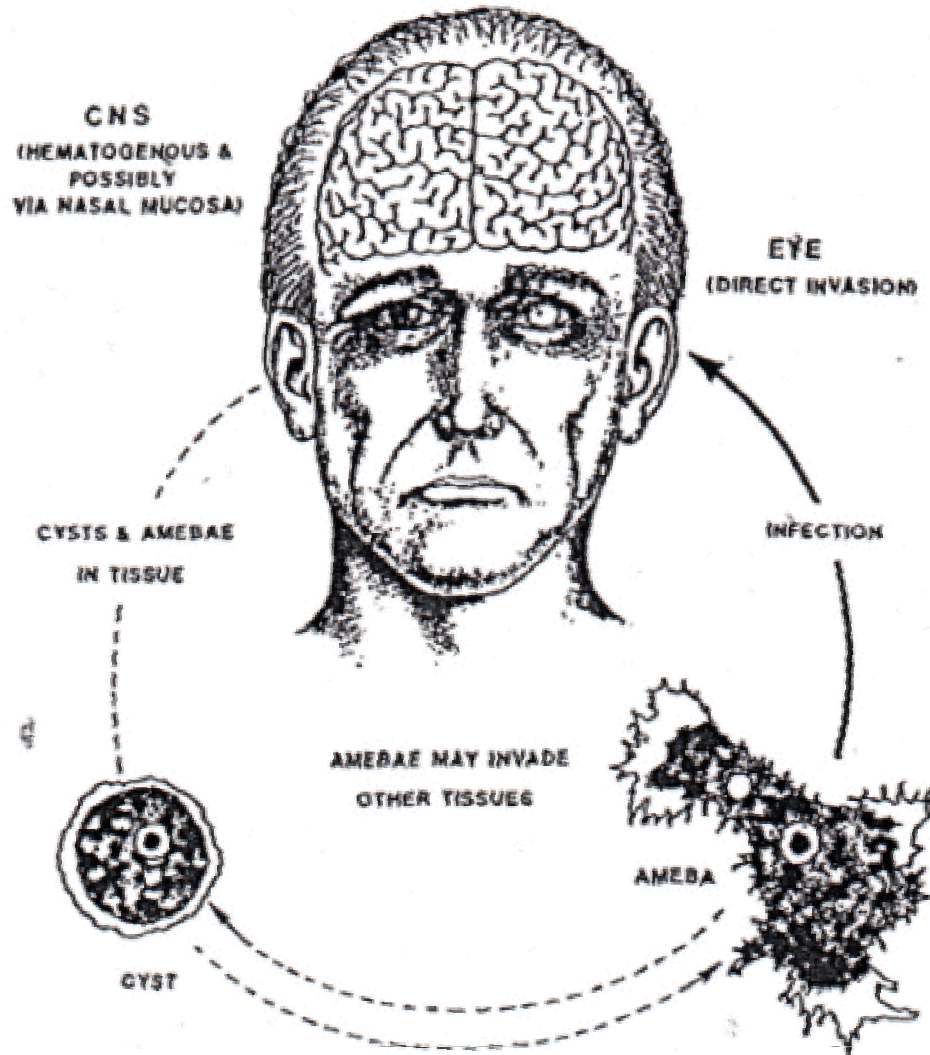
Two types of illnesses are most commonly associated with *Acanthamoeba* spp. These are *Acanthamoeba* keratitis (an infection of the eye) and granulomatous amoebic encephalitis (GAE). GAE infection is usually considered opportunistic. Keratitis occurs primarily in healthy individuals who wear contact lenses and GAE occurs primarily in immuno-deficient individuals. A comparison of the clinical and pathological features of the two diseases is listed in Table 5.1.

Risk of acanthamoebic eye infection is associated with eye trauma (physical injury to the eye) or wearing of contact lens in conjunction with exposure to water containing *Acanthamoeba* such as tapwater, hot tubs, natural springs, bottled water, and non-sterile waters used to store contact lenses. Reports indicate that 85% of cases are associated with individuals who wear contact lenses.

Table 5.1 Comparison of Clinical and Pathological Features of Granulomatous Amoebic Encephalitis (GAE) and *Acanthamoeba* Keratitis (AK)

Features	GAE	AK
Predisposing Factors	Immunodeficiency; AIDS; Debilitating chronic disease	Good health, corneal trauma, contaminated contact lens wearing
Epidemiology	Worldwide	Worldwide
Usual Portals of Entry	Lungs; skin; nose; neuroepithelium	Corneal abrasion
Incubation Period	Probably weeks to months	Probably days
Clinical Course	Subacute or chronic (several weeks to months);	Subacute or chronic
Prognosis	Almost always fatal	Good if properly treated
Clinical Symptoms and Signs	Personality changes; confusion; seizures; nausea; headache; dizziness	Eye pain; typical corneal ring "infiltrate"; photophobia; blurred vision
Treatment	Itraconazole; Miconazole; Sulfametazine; Pentamididine IV (in vitro)	Polyhexamethylene biguamide; Propamidine isethionate

Figure 5.1 Life cycle of *Acanthamoeba* spp. and Human Infection



Granulomatous amebic encephalitis or GAE is a chronic illness of the central nervous system that affects the brain and is associated with *Acanthamoeba* spp. It is an infection primarily of the immunocompromised individual which usually leads to death.

5.1 Eye Infections (Acanthamoebic Keratitis)

Acanthamoeba species cause acanthamoebic keratitis, a painful, vision-threatening disease of the cornea. The infection is associated with minor corneal trauma or the use of contact lenses in normal, healthy people. Males and females are equally affected. *Acanthamoeba* keratitis is characterized by severe ocular pain, a complete or partial paracentral stromal ring infiltrate, recurrent corneal breakdown of the epithelium and a corneal lesion refractory to commonly used ophthalmic antibacterial medication. Clinical features of the disease are in Table 5.2.

**Table 5.2 Characteristics and Symptoms of Patients
with *Acanthamoeba* Keratitis**

-
- Young, healthy individuals
 - Soft contact lens wearers
 - Non-preserved or non-sterile solution used for storage of contact lens
 - Eye trauma
 - Usually one eye affected
 - Extreme eye pain
 - Corneal breakdown of the epithelial
 - Late in the infection, a corneal ring infiltrate is seen
-

Some species of *Acanthamoeba* were not found to be associated with eye disease until the early 1970's. Jones *et al.* (1973), Jones *et al.* (1975), and Visvesvara *et al.* (1975) described the case of a rancher who scraped his eye while bailing hay and rinsed it with tap water pumped into his house from a well that used unfiltered river water. The authors also described an infection in a young female nurse who had no history of eye disease, and a fatal infection in a 7-year-old boy who had played in drainage ditches near his home. Nagington *et al.* (1974) described an eye infection in a 32-year-old schoolteacher who did not have a history of exposure to contaminated water, and a second fatal case in a 59-year-old farmer who was hit in the eye by a tree branch. Jones *et al.* (1975) also described a case involving a 58-year-old farmer who had been exposed to

dust while baling barley on his farm. The infection failed to respond to treatment and had to be surgically removed.

Other cases of physical damage include irritation by an insect (Hamburg and DeJonckheere, 1980), contamination by barley dust (Jones *et al.*, 1975), and wind surfing (Volker-Dieben *et al.*, 1980). The effects from eye trauma ranged from successful treatment, corneal replacement, loss of the affected eye and, rarely, death of the patient. Jones *et al.* (1975) described a fatal case in a young boy who was suspected of playing in a watering trough for cattle.

The number of eye infections reported in the 1970's generally were unique case histories involving injury. All of this changed when some of the eye infections thought to be of viral origin were found to be caused by *Acanthamoeba* (MMWR, 1987). Ormerod and Smith (1986) reviewed the histories of 42 cases of keratitis in California that occurred between 1977 and 1984 and suggested that it was likely that extended wear lenses might increase the risk of microbial keratitis. Stehr-Greene *et al.* (1987) conducted a case-control study to obtain information on the role of contact lens sanitary practices on injury to the eye. They studied 27 patients with keratitis and 81 uninfected individuals (controls) in order to compare lens care practices. Patients with keratitis were found more likely to use homemade solutions than controls (78 versus 17 percent) and were more likely to wear lenses while swimming (63 versus 30 percent). The authors found that microbial contaminants other than *Acanthamoeba* were present in 1 of 59 commercial saline solutions, 11 of 11 homemade solutions, and 23 of 29 bottles of non-sterile distilled water. Thus, there is little doubt that microorganisms in non-sterile cleansing solutions may become established in contact lens cases, perhaps on the lenses themselves, and lead to serious eye disease. Badendoch (1991), Martinez and Visvesvara (1997) have reviewed most of the literature on amoebic eye diseases beginning with some of the earliest recognized cases and noted that successful outcomes depended on early diagnosis and treatment. Martinez and Visvesvara (1997) estimated that, as of January 1996, more than 750 cases of amoebic keratitis have been reported worldwide.

There are several important risk factors associated with acanthamoebic keratitis. The vast majority of patients have at least one of these identifiable factors, which include corneal trauma, exposure to contaminated water, and contact lens use. Approximately 71 to 85% of patients with acanthamoebic keratitis are contact lens wearers (Moore and McCulley, 1989; Moore *et al.*, 1985).

No single type of contact lens has been excluded from association with acanthamoebic keratitis. People with daily wear soft contact lenses account for approximately 75% of the cases, people with extended wear contact lenses account for about 14%, people with hard contact lenses account for about 6%, and people with rigid gas permeable lenses account for about 4% (Moore *et al.*, 1985). In another study, Stehr-Green *et al.* (1987) reported that most patients (95%) had at least one risk factor for acanthamoebic keratitis, the 85% who wore contact lenses, most wore

daily wear (56%) or extended wear soft (19%). Some patients (including both contact lens wearers) (26%) had a history of corneal trauma before developing acanthamoebic keratitis, and 25% of patients had a history of exposure to contaminated water.

Two studies have identified tapwater washing of lens cases in cases of *Acanthamoeba* (Seal *et al.*, 1997, Ledee *et al.*, 1996). Ledee *et al.*, 1996 using molecular fingerprinting techniques established domestic tapwater in the United Kingdom as the source of contamination in contact lens wearers. Similarly, contact lens wearers who have been exposed frequently to hot tubs or natural springs are at risk of developing acanthamoebic keratitis (Wilhelmus and Jones, 1991).

5.1.1 Symptoms of *Acanthamoeba* Keratitis

Clinical symptoms are usually a history of pain and the formation of a whitish halo or ring infiltrate around the periphery of the cornea (Figure 5.2). Although most cases present a history of contact lens wear, the infections are also associated with a foreign object or physical trauma in the affected eye. A normal eye is shown in Figure 5.3.

Figure 5.2 Slit lamp view showing a paracentral complete ring infiltrate of the cornea. The ring infiltrate is diagnostic of *Acanthamoeba* infections (Theodore *et al.*, 1985)

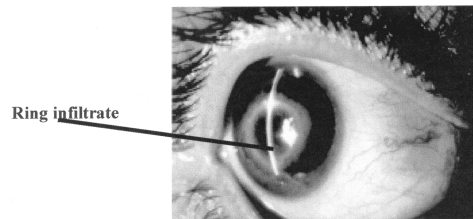
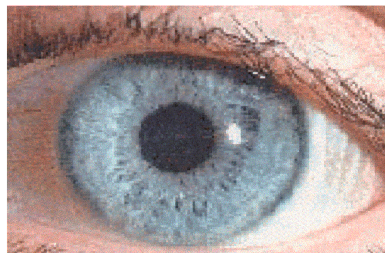


Figure 5.3 Normal eye



5.1.2 Diagnosis of *Acanthamoeba* Keratitis

While positive diagnosis of acanthamoebic keratitis can be made by *in vivo* confocal microscopy, diagnostic tests usually rely on demonstrating amoebae on corneal scrapings or biopsy material (Seal *et al.*, 1996). Samples of corneal epithelium and any infiltrated stroma are removed under local anesthetic, and contact lenses and storage cases may also be cultured. The most common method is to inoculate the sample into the center of a non-nutrient agar plate seeded with *E. coli* (Singh and Petri, 2000). With incubation at 32°C in air, migration tracks are usually visible within 48 hours. Positive identification requires some experience, and it is useful to incubate a control plate that is not inoculated with a clinical specimen.

5.1.3 Identification Procedures

Standard methods for morphological characterization, isoenzyme electrophoresis, immunological techniques, and temperature tolerance tests have been published and widely used (Singh and Petri, 2000). Results obtained by using one or more of these techniques, coupled with animal pathogenicity tests, and the shape and size of cysts, are often adequate for identifying more commonly occurring species of *Acanthamoeba*.

Corneal biopsy of infected eye are usually sufficient for confirming infection by amphizoic amoebae. However, it may be possible to make an identification of genus when distinctive double-walled wrinkled cysts suggest a Group III species of *Acanthamoeba*. When amoebae from corresponding pieces of tissue appear on culture plates, the cysts are often distinctive enough to place the organism in *Acanthamoeba*. Keys to soil amoebae (Page, 1976; 1988) or photographs (Pussard and Pons, 1977), often are sufficient for identifying some of the well-known species. Biochemical methods for obtaining isoenzyme profiles (deJonckheere and Michel, 1988) are extremely useful in combination with morphological features for identifying most amoebae (Sawyer, 1992). Griffin (1972) used thermotolerance as one method for screening amoebae for pathogenicity. Pathogenicity can be assessed by a number of methods (see Section 5.1.6).

5.1.4 Treatment of *Acanthamoebic* Keratitis

In the first 10 years after the emergence of acanthamoebic keratitis as a clinical problem, treatment was usually unsatisfactory, employing a wide variety of topical agents in combination. In 1985, Wright *et al.* reported successful medical treatment using propamidine isethionate (Brolene) 0.1%, an aromatic diamidine, applied topically with dibromopropamidine ointment 0.15%, and followed by treatment with neomycin when signs of toxicity occurred. The success of the treatment was attributed to the amoebicidal activity of both propamidine and dibromopropamidine, although subsequently dibromopropamidine was generally omitted from the regimen. Further experience showed that a medical cure with propamidine therapy was most

likely to be achieved if treatment began early in the course of the disease (Moore and McCulley, 1989). Propamidine was generally combined with neomycin, initially instilled hourly and tapered slowly over several months after improvement was noted. However, in some patients results were still poor, and more effective compounds were sought (Ficker, 1988). Successful treatment using propamidine with miconazole 1% (often with neomycin sulfate-polymixin B sulfate-gramicidin) has been reported (Berger *et al.*, 1990), as has combination therapy with oral itraconazole, with topical miconazole 0.1% and debridement (Ishibashi *et al.*, 1990). Another combination regimen is topical clotrimazole 1-2% with propamidine and neomycin sulfate-polymixin B sulfate-gramicidin; in a series reported recently a medical cure was achieved in 11 of 14 patients with eye infections using this combination (D'Aversa *et al.*, 1995).

In the early 1990's, *in vitro* sensitivity studies showed that the cationic disinfectant polyhexamethylene biguanide (PHMB) was highly effective in killing both cysts and trophozoites, and in 1992 Larkin *et al.* reported its successful clinical use at a concentration of 0.02%. The main theoretical advantage of PHMB over other compounds seems to be its consistently high cysticidal activity against a number of strains, compared with other compounds that may be active against some strains but relatively ineffective against others. Another factor is that in contrast to propamidine, PHMB does not appear to be associated with toxicity problems (Johns *et al.*, 1988). Clinical experience with PHMB (usually in combination with propamidine) has shown that if used early enough in the course of the disease the prognosis is very good, and penetrating keratoplasty is unlikely to be necessary (Illingworth *et al.*, 1995).

Recently the use of the diamidine derivative hexamidine, which appears to have a greater cysticidal activity than propamidine, has been reported (Brasseur *et al.*, 1994). The use of chlorohexidine 0.02% as an alternative to PHMB has also been reported, resulting in a medical cure in 11 of 12 patients (Seal *et al.*, 1996).

5.1.5 Incidence of *Acanthamoeba* Keratitis

Acanthamoeba keratitis is not a reportable disease in the United States so the true incidence is not known. Published work suggests an incidence of 0.58 to 0.71 cases/1,000,000 in the general population, and 1.65 to 2.01/10⁶ among contact lens wearers (Schaumberg *et al.*, 1998). One study in the United Kingdom reported an incidence of 149/10⁶ among contact lens wearers (Seal, 2000). A summary of studies reporting the incidence of *Acanthamoeba* keratitis is shown in Table 5.3. The incidence of all causes of microbial keratitis (largely bacterial) is about 400/10⁶ among contact lens wearers. Worldwide, the incidence of microbial keratitis has been reported to range from 1.1 to 2,000/10⁶ among contact lens wearers (Cheng *et al.*, 1999). Difficulties in the diagnosis of *Acanthamoeba* keratitis probably lead to an underestimation of the true number of cases. An estimate of *Acanthamoeba* keratitis known cases in the U.S. stood at 500 with over 3000 cases worldwide (Martinez and Visvesvara, 2001).

Table 5.3 Worldwide Incidence of *Acanthamoeba* Keratitis

Incidence per 1,000,000	Population	Country	Year(s)	Reference
1.65 to 2.01	Contact Lens Wearer (CLW)	USA	1985-1987	Schaumberg <i>et al.</i> , 1998
1.1	CLW	Netherlands	1996	Cheng <i>et al.</i> , 1999
149	CLW	UK	1996	Seal, 2000
0.58 to 0.71	General Population (GP)	USA	1985-1987	Schaumberg <i>et al.</i> , 1998
1.40	GP	UK	1996	Radford <i>et al.</i> , 1998
1.30	GP - Iowa well water	USA	1993-1994	Meier <i>et al.</i> , 1998
14.3	GP - during flooding municipal systems	USA	1993-1994	Meier <i>et al.</i> , 1998

5.1.6 Pathogenicity

The pathogenesis of acanthamoebic keratitis has been suggested to follow two pathways (Alizadeh *et al.*, 1995). The first pathway is restricted to the epithelium without involvement of the stoma and has a good prognosis. The second pathway culminates in the parasites entering the stoma, resulting in extensive necrosis, and edema. The first step in the initiation of infection is the attachment to the epithelial surface. Amoebae bind to the corneal surface and produce epithelial thinning and necrosis.

The pathogenicity of *Acanthamoeba* spp. is related to its ability to attach to corneal epithelial cells. Khan (2001) found that *Acanthamoeba* exhibited higher number of acantodia (structures associated with the binding of amoeba to the target cells in the eye) as compared to non-pathogenic *Acanthamoeba*. Additional results indicated that phagocytosis occurs in the pathogenic amoeba by formation of amoebastone (characteristic of amoeba phagocyte) and that *Acanthamoeba* phagocytosis may be both an efficient means of obtaining nutrients and a significant factor in pathogenesis of *Acanthamoeba* infections. Khan *et al.* (2001) differentiated pathogenic *Acanthamoeba* by their ability to produce cytopathogenic effects (CPE) on corneal

epithelial cells in culture. They also reported that pathogenic *Acanthamoeba* showed growth on higher osmolarity (one molar mannitol) while growth of non-pathogens was inhibited. The pathogenic potential of *A. castellani* isolates was correlated with the ability to bind to the corneal epithelium, respond chemotactically to corneal endothelial extracts, elaborate plasminogen activators, and produce cytopathogenic extracts (van Klink *et al.*, 1992).

The 18S rRNA gene (Rns) phylogeny of *Acanthamoeba* has been investigated as a basis for improvements in the nomenclature and taxonomy of the genus (Stothard *et al.*, 1998). Twelve lineages referred to as T1-T12 have been identified with most of the keratitis causing strains belonging to group T4 (Stothard *et al.*, 1998; Walochink *et al.*, 2000). More recently type T6 has also been reported to be associated with keratitis (Walochik *et al.*, 2000).

Another factor in the pathogenicity of *Acanthamoeba* may be an individual's ability to produce antibodies in tears (Alizadeh *et al.*, 2001). The presence of serum antibody in 50 to 100% of the population suggests that exposure to *Acanthamoeba* species is ubiquitous (Cursons *et al.*, 1980; Cerva, 1989). However, patients with *Acanthamoeba* keratitis have significantly higher anti-*Acanthamoeba* IgG antibody titers than healthy subjects (Alizadeh *et al.*, 2001). In contrast anti-*Acanthamoeba* tear IgA was significantly lower in patients with *Acanthamoeba* keratitis in comparison with healthy subjects. This suggests that a low level of anti-*Acanthamoeba* IgA antibody in the tears appears to be associated with *Acanthamoeba* keratitis.

In summary, the pathogenic potential of *Acanthamoeba* appears to be related to certain strains and the ability of the host to produce IgA antibodies in the tears.

5.1.7 Immunity

The presence of serum antibody in 50 to 100% of the population suggests that exposure to *Acanthamoeba* species is common. (Cursons *et al.*, 1980; Cerva, 1989). These antibodies were shown to be capable of neutralizing cytopathogenic effects of *Acanthamoeba* (Ferrante, 1991). Patients with *Acanthamoeba* keratitis have a significantly higher anti-*Acanthamoeba* IgG antibody titer than healthy subjects (Alizadeh *et al.*, 2001). In contrast anti-*Acanthamoeba* tear IgA was significantly lower in patients with *Acanthamoeba* keratitis in comparison with healthy subjects. This suggests that a low level of anti-*Acanthamoeba* IgA antibody in the tears appears to be associated with *Acanthamoeba* keratitis. Persistent corneal and scleral inflammation observed following cases of *Acanthamoeba* keratitis is not always caused by active amoebic infection but can be due to persisting acanthamoebic antigens. Yang *et al.* (2001) found that *Acanthamoeba* cysts were found to persist for up to 31 months in the eye after treatment although trophozoites were no longer present. They hypothesized that *Acanthamoeba* cysts can remain in corneal tissue for extended periods of time and may cause persistent inflammation in the absence of active amoebic infection.

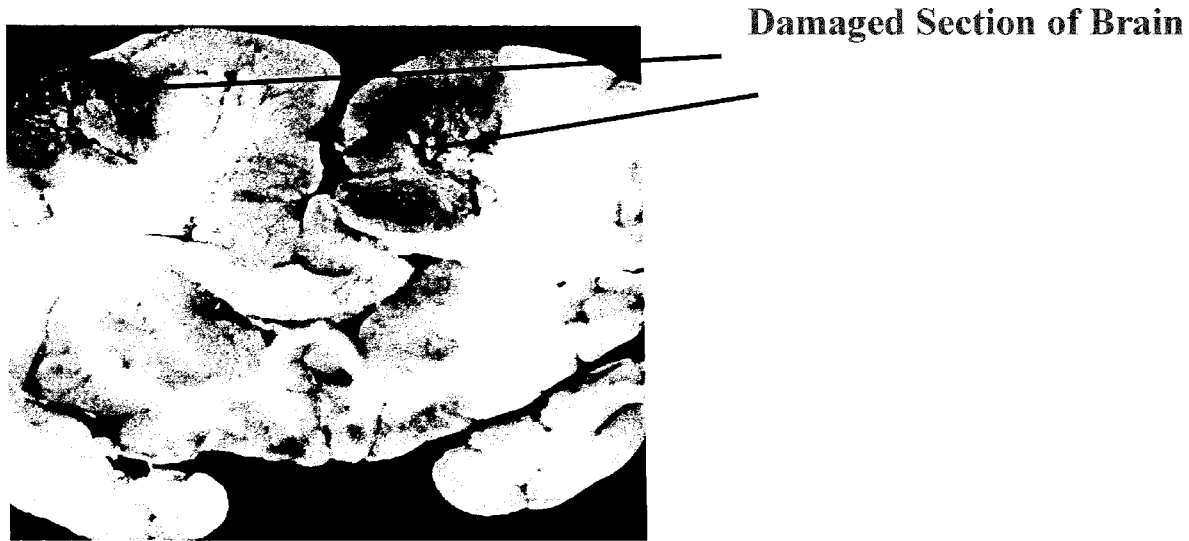The feasibility of inducing protective immunity to *Acanthamoeba* keratitis has been tested in a pig model (Alizadeh *et al.*, 1995). It was shown possible to induce immunity in 50% of the animals by subconjunctival injection of the parasites, and in 100% by a combination of intramuscular and subconjunctival injection, whereas corneal infection alone did not confer immunity to subsequent infection.

5.2 Granulomatous Amoebic Encephalitis

Granulomatous amoebic encephalitis (GAE) caused by *Acanthamoeba* spp. is the second major infection associated with *Acanthamoeba*. GAE is a chronic, progressive disease of the central nervous system occurring most often in persons with poor immune systems or other debilitating health problems. Predisposing factors include chemotherapy, dialysis, diabetes mellitus, treatment with steroids, chronic alcoholism, smoking, bone marrow or renal transplantation, or acquired immunodeficiency syndrome (Marciano-Cabral *et al.*, 2000). Chronic skin infections have been reported from patients with GAE. However, it is not known whether skin lesions provide the primary site of infection or represent terminal dissemination of *Acanthamoeba* from the lungs to other sites (Marciano-Cabral *et al.*, 2000). In the majority of AIDS patients, skin lesions and sinusitis are common features. It may be caused by *A. astronyxis*, *A. palestinensis*, *A. culbertsoni* and *A. castellanii*. It spreads from lung or skin lesions to the central nervous system, resulting in neurologic deficits that progress over days or weeks to meningoencephalitis and death.

Another free living amoeba, *Naegleria fowleri*, was later discovered to cause an aseptic meningitis that was usually fatal (Ma *et al.*, 1990). The term primary amoebic meningoencephalitis, or PAM, was proposed for infection by *Naegleria* (Butt, 1966), and the term granulomatous amoebic encephalitis, or GAE, was proposed for infections by *Acanthamoeba* (Martinez, 1980). The two disease entities differ since PAM occurs most often in young people, is associated with swimming and has a rapid onset of symptoms. In contrast, GAE occurs most often in patients with poor immune systems or patients suffering from long-standing health problems regardless of age. Granulomatous amoebic encephalitis caused by *Acanthamoeba* or *Balamuthia* is now recognized as a disease occurring most often in persons with poor immune systems or suffering from some other debilitating health problem (e.g., alcoholism, diabetes, smoking or acquired immunodeficiency syndrome [AIDS]) (Figure 5.4). The amoebae are believed to enter the bloodstream, probably via the nose, lungs, or breaks in the skin following injury or trauma. They then affect various organs by hematogenous spread.

Figure 5.4 Granulomatous amoebic encephalitis (GAE). Section through the brain of a fatal case caused by *Balamuthia mandrillaris* (Photograph courtesy of Dr. Julio Martinez, University of Pittsburgh).



Balamuthia has been identified in approximately 40 patients in the United States (U.S.), including >10 with AIDS infection (Martinez *et al.*, 1997, Visvaresvara, 2001). In contrast, *Acanthamoeba* has accounted for approximately 84 (~50 with AIDS) cases in the U.S. and 120 worldwide (Martinez *et al.*, 1997, Visvaresvara, 2001). The disease may be the end result of long-term injury. Fatal infections probably occur in individuals with extensive damage to the central nervous system and internal organs prior to the manifestation of overt clinical symptoms.

The exact pathway of amoebae entering the brain is difficult to determine since, in most cases with a fatal outcome, there has been a history of predisposing factors. It is believed that the amoebae are spread throughout the body via blood vessels (hematogenous spread), after entry through the nasal passages, lower respiratory system or breaks in the skin caused by injury (Ma *et al.*, 1990). Patients who have been treated for GAE range from children to elderly adults with a clinical history of illness ranging from about 1 week to 6 months (Martinez *et al.*, 1977). Symptoms of neurological disease upon admission to a hospital are varied, including headache, drowsiness, low-grade fever and stiffness of the neck. Other symptoms that may appear early in the disease are personality changes, seizures, nausea, vomiting or lethargy (Martinez and Visvesvara, 1991). Thorough diagnostic procedures are necessary to recognize amoebic meningoencephalitis because upon initial examination, the disease is not always easy to

distinguish from bacterial meningitis, tuberculous meningitis, brain tumors or viral meningitis (Martinez and Visvesvara, 1997). Martinez and Janitschke (1985) reviewed 33 cases of GAE and listed several illnesses associated with the patients who had the disease. They included skin ulcers, cirrhosis of the liver, hepatitis, pneumonitis, renal failure, collagen-connective tissue disease and pharyngitis. Predisposing factors mentioned by the authors included chemotherapy, radiation treatment, steroids, broad spectrum antibiotics, alcoholism, splenectomy and peritoneal dialysis.

5.2.1 Diagnosis and Treatment of GAE

Patients with confirmed GAE usually are chronically ill, immunosuppressed, or debilitated by other causes. By the time a diagnosis has been made, the central nervous system may have been invaded, probably via the nasal passages, respiratory tract or skin (Martinez, 1993). The diagnosis may be questionable at first because of the possibility of brain tumor, abscess or intracerebral hematoma (Visvesvara *et al.*, 1997). Successful treatment is rare and infection usually results in the death of the patient. *In vitro* studies have shown that diamidine derivatives such as pentamidine, propamidine, miconazole, ketoconazole and 5-fluorocytosine may be effective in treating GAE (Martinez *et al.*, 1997). There are some occasions when skin nodules harboring *Acanthamoeba* are detected prior to spreading to internal organs and the central nervous system. Visvesvara *et al.* (1997) suggested that when skin nodules or ulcers are present, treatment may be tried using topical chlorhexidine gluconate and intravenous pentamidine.

In spite of the poor prognosis for most patients with GAE, efforts to find at least a partially successful treatment are in progress. A new class of peptide compounds called magainins that may have amoebostatic and amoebicidal properties when used with other amoebicidal agents (Martinez *et al.*, 1997, Schuster and Jacob, 1992). Schuster and Visvesvara (1998) tested antimicrobials and phenothiazine compounds against amphizoic amoebae and found the levels affecting them probably were too high for clinical use. In other efforts, Chu *et al.* (1998) studied the effects of plant extracts that were amoebicidal or induced encystment.

5.2.2 Incidence of GAE

The global incidence as of 2000 stood at 120 cases of recorded GAE cases, 84 of those occurred in the U.S. and over 50 of the GAE cases were found in AIDS patients (Martinez and Visvesvara, 2000). There is general agreement that both GAE and keratitis have increased in the last 10 years in the U.S. because of the increase in the use of contact lens wearers of all ages for various reasons including athletic and cosmetic, and the increase in the number of immunosuppressed individuals (Marciano-Cabral *et al.*, 2000; EPA, 1998).

5.2.3 Pathogenesis and Immunity

The pathogenesis of GAE is complex and poorly understood (Martinez and Visvesvara, 1997). In GAE, the immunity is predominantly T-cell mediated, therefore the diminution of CD⁺ and T helper lymphocytes, as occurs in AIDS patients, enables the proliferation of free-living amoebae. Ulceration of the skin containing both amoebic trophozoites and cysts suggests also the portal of entry into the bloodstream. In experimental animals, the olfactory neuroepithelium has also been found to be a possible portal of entry (Janitschke *et al.*, 1996). The incubation period of GAE is unknown but is probably longer than 10 days. The ability of the *Acanthamoeba* to produce necrosis of the brain tissue is probably due to an enzymatic action induced by lysosomal hydrolases and phospholipase that can degrade phospholipids of the myelin sheaths (Martinez and Visvesvara, 1997).

Studies in mice have demonstrated that it is possible to immunize animals against *Acanthamoeba* meningoencephalitis (Culbertson, 1971; Rowan-Kelly and Ferrante, 1984). Animals immunized intraperitoneally with sonicated trophozoites of *A. culbertsoni* were highly resistant to intranasal infection with the organism. Those immunized with a non-pathogenic *A. culbertsoni* or *A. polyphaga* were not protected against infection with *A. culbertsoni*.

5.3 GAE in Domestic Animals and Wildlife

Several reports of amoebic infections in animals appeared in the literature at about the same time as they were found in fatal infections in humans. The principal difference between human and animal infection is that infection in humans occurs primarily in persons with deficient immune systems or those taking immunosuppressive drugs, this is not found in cases involving animals. Kadlec (1978) carried out one of the most extensive surveys of infection in domestic animals by amoebic infection. He identified *Acanthamoeba* spp. from bulls, cows, a rabbit, pigeons and turkeys. Infections in animals probably occur by the same routes as reported for humans. It has also been described in dogs by several investigators (Ayers *et al.*, 1972, Bauer *et al.*, 1993). Infections in the lung of water buffalo and bulls could have been nasopharyngeal from drinking unclean water (Dwivedi and Singh, 1965, McConnell *et al.*, 1968).

Evidence for water as a source of infection in animals by *Acanthamoeba* is found in reports of the amoebae in the gills, spleen, urinary bladder or blood of wild caught and ornamental fish (Taylor, 1977, Dykova *et al.*, 1996, Booton *et al.*, 1999).

5.4 Other Infections Caused by *Acanthamoeba*

Occasional infections by *Acanthamoeba* spp. have included a purulent discharge from an ear (Lengy *et al.*, 1971), a granulomatous skin lesion (Gullet *et al.*, 1979), rhinosinusitis in an AIDS

patient (Teknos *et al.*, 2000) and possible association with intestinal disorders (Hoffler and Rubel, 1974; Mehta and Guirges, 1979; Thamprasert *et al.*, 1993).

5.5 Immunocompromised Individuals

Several reports of *Acanthamoeba* infection in AIDS patients involved the skin, as well as other tissues and, in most cases, there was a fatal outcome in spite of treatment. In AIDS patients it is not always absolutely clear whether the AIDS virus or the amoebae were the primary cause of death. The infection with free-living amoebas is a terminal event. Individuals with deficient immune systems, whether natural or acquired, represent a segment of the population that are most likely to succumb to infections with microbial pathogens including amphizoic amoebae. Gonzalez (1986) reported a case resulting in death in a 29-year-old patient with AIDS. At autopsy, amoebae were found in the paranasal sinuses, a calf nodule, and in an abscess of the left leg, but not in the brain. The following year Wiley *et al.* (1987) examined a 34 year-old patient with a history of nasopharyngeal allergies and infections with *Giardia lamblia* and *Cryptosporidium* spp. The patient underwent an appendectomy and developed a hard-skin nodule above the surgical scar. The patient stated that he had noticed painful skin lesions prior to surgery. At autopsy, amoebae were found in the brain and the skin. Tissue fragments placed in kidney cell tissue cultures yielded amoebae identified as *Acanthamoeba culbertsoni*. Another case involving skin infection was reported by Friedland *et al.* (1992). They treated an AIDS infected 8 year-old Hispanic male who died of the infection. The patient had a persistent nasal discharge and skin nodules that eventually became ulcerated and 2 to 4-mm deep prior to death. Gordon *et al.* (1992) described a fatal case in an AIDS patient caused by *A. polyphaga*, and Gardner *et al.* (1991) described a case probably caused by *A. rhyodes*. Other fatal cases in AIDS patients followed in 1994 (Park *et al.*), and 1996 (Telang *et al.*, 1996).

Visvesvara *et al.* (1983) described a fatal case of GAE that involved a patient with a liver transplant. Twenty-six days after the transplant, the patient was readmitted to the hospital with pneumonia and cytomegalovirus infection. At autopsy, amoebae were noted in the brain, lungs, blood vessel walls, adrenal and thyroid glands, lymph nodes, skin and breast tissue. Borochovit *et al.* (1981) identified *A. castellanii* from a bone graft in a diseased mandible. Anderlini *et al.* (1994) described two cases of fatal amoebic encephalitis in patients with leukemia, who had received bone marrow transplants.

5.6 Incidence to Children

Children do not appear more likely to develop ocular *Acanthamoeba* infections. Only 13% of all contact lens wearers are under 17 years of age, but the potential for keratitis may be increasing in children because of color lens swapping by teenagers (Contact Lens Council, 2000) (Figure 5.5). In general all types of microbial keratitis occur less in childhood and are largely associated with trauma or preexisting corneal disease (Cruz *et al.*, 1993).

5.7 Effect of Endosymbiosis on Virulence

Acanthamoeba spp. has been demonstrated to develop endosymbiotic relationships with a number of waterborne bacteria, including *Legionella pneumophila* and *Mycobacterium avium* (Table 3.3). This relationship may be important both in the growth and survival of these opportunistic pathogens in drinking water systems, and in their ability to cause disease in humans.

Cirillo *et al.* (1997) found that *Mycobacterium avium* replicates within *Acanthamoeba castellanii* and that this association enhanced both the entry and intracellular replication compared to the growth of the bacteria in broth culture. Furthermore, amoeba-grown *M. avium* was also more virulent in a mouse model. They also found that the highest growth rate of the *M. avium* in the amoebae was near 37°C. From this observation, they suggested that if growth of *M. avium* in water environments occurs primarily within protozoa, the fact that *M. avium* has temperature-dependant growth in amoebae may explain why *M. avium* infections are more frequently associated with warm water supplies. It was also found that non-pathogenic strains of *Mycobacterium* were readily killed within the amoeba.

Cirillo *et al.*, 1999 found *Legionella pneumophila* grown in *A. castellanii* to be at least 100-fold more invasive for macrophages than when grown on agar. They also provided evidence that amoeba grown *L. pneumophila* expressed different proteins that may have been related to its enhanced invasiveness. The authors also suggested the replication of *L. pneumophila* in protozoans present in domestic water supplies may be necessary to produce bacteria that are competent to enter mammalian cells and produce human disease. A recent study has suggested that endosymbiosis enhances the virulence of the *Acanthamoeba*. Fritsche *et al.* (1998) reported that endosymbiont-infected amoebae produced a statistically significant enhancement in cellular destruction of human embryonic tonsillar (HET) cell monolayers in comparison to uninfected amoeba. Neither the bacteria or *Acanthamoeba* alone were capable of producing cellular destruction (i.e. cytopathic effects). Whether such enhanced pathogenic effects occurs in clinical *Acanthamoeba* infections is unknown.

6.0 HEALTH EFFECTS

6.1 The Organism and its Occurrence (Exposure)

Certain species of the genus *Acanthamoeba* have been associated with eye disease in humans. Five species demonstrated to be associated with eye disease are listed in Table 6.1. The majority of the infections (85%) in the United States are associated with the use of contact lenses, and the remainder with some trauma to the eye (Stehr-Green *et al.*, 1987). Infection results from the exposure to *Acanthamoeba* through improper storage of lenses, wetting of the lenses with unsterile solutions, improper disinfection of lenses, or swimming while wearing contact lenses. One epidemiological study suggests that increased risk may exist from municipal supplies which have been subjected to flooding (Meier *et al.*, 1998). The concentration of free-living amoebae in surface waters may vary seasonally creating a greater exposure at certain times of the year. *Acanthamoeba* is common in the aquatic environment (see section 4.0) and its cyst form is resistant to inactivation by chlorine (Radford *et al.*, 1998). Wetting or storage of lenses in tapwater appear to be the most significant route of exposure for contact lens wearers.

6.2 Epidemiological Evidence for *Acanthamoeba* Keratitis Transmission by Tapwater

Molecular based investigations have established domestic tapwater in the United Kingdom as a proven source of *Acanthamoeba* infection in lens wearers (Ledee *et al.*, 1996). The organisms have been isolated from household taps and probably feed on the microbial biofilm within the distribution system. An epidemiological study in the midwest United States suggested that an epidemic of presumed *Acanthamoeba* infections was associated with municipal water supplies subjected to flooding during 1993-1994 (Mathers *et al.*, 1996; Meier *et al.*, 1998). The incidence of presumed *Acanthamoeba* was ten times greater (1.30 vs. 14.3 cases/10⁶) in areas affected by flooding. The incidence was also significantly lower if the home was supplied with tapwater from a private well. In both of these studies the authors used tandem scanning confocal microscopy and confirmatory cytopathologic findings to diagnose the cases. However, the authors were unable to culture *Acanthamoeba* from individuals with keratitis. The authors suggested several reasons for their failure to culture the organism including (1) the infections were caused by a new species with different growth requirements (2) the inoculum was insufficient (3) an inhibitor was present (4) the organisms were present but non-viable and (5) the infections were caused by another organism.

Table 6.1 Human Infection Caused by Species of *Acanthamoeba*

Species of <i>Acanthamoeba</i>	CNS infection	Eye infection	Other tissues	Reference
<i>A. astronyxis</i>	X		Adrenal, lymph node, sinus, skin, thyroid	Gullett <i>et al.</i> (1979)
<i>A. castellanii</i>	X	X	Lung, prostate, bone, muscle, sinus, skin	Martinez (1982) Martinez <i>et al.</i> (1977) Moore <i>et al.</i> (1985) Borochovizt <i>et al.</i> (1981) Gonzalez <i>et al.</i> (1986)
<i>A. culbertsoni</i>	X	X	Liver, spleen, uterus, skin	Martinez <i>et al.</i> (1977) Wiley <i>et al.</i> (1987) Mannis <i>et al.</i> (1986) May <i>et al.</i> (1992)
<i>A. divionensis</i>	X			DiGregorio (1992)
<i>A. griffini</i>		X		Ledee <i>et al.</i> (1996)
<i>A. hatchetti</i>		X		Cohen <i>et al.</i> (1985)
<i>A. healyi</i>	X			Kim <i>et al.</i> (2000)
<i>A. palestinensis</i>	X			Ofori-Kwakye <i>et al.</i> (1986)
<i>A. polyphaga</i>		X		Singh and Petri (2000)
<i>A. rhyodes</i>	X	X		Singh and Petri (2000)

CNS - Central Nervous System

6.3 Resistance to Drinking Water Treatment and Disinfection

No studies could be found on the effectiveness of drinking water treatment on the removal of *Acanthamoeba* cysts or trophozoites. Given the large size of the trophozoites (15 to 45 µm) and cysts (15 to 28 µm) they would be easily removed by filtration in a conventional water treatment plant. Their isolation from tapwater suggests that they can certainly colonize taps and feed on bacteria in the biofilm in distribution systems. De Jonckheere and Van de Voorde (1976) reported *Acanthamoeba* cysts to be very resistant to inactivation by chlorine, bromine, and

iodine. The chlorine resistance of two different strains varied considerably. A 99.99% (4 log₁₀) inactivation of a more sensitive strain was achieved with 16mg/liter within one hour. A 4-log₁₀ decrease was not achieved after 24 hours with 6 mg/liter.

The cysts have also been found to be very resistant to ultraviolet light. Change *et al.* (1985) found the cysts of *A. castellanii* to be more resistant than *Bacillus subtilis* spores. A dose of approximately 70 mW-sec/cm² was required for a 99% (2 log₁₀) inactivation of the cysts. The viability of the cysts was detected with a plaque assay on a lawn of *Escherichia coli* bacteria, requiring both excystation and growth of the organism.

In contrast the trophozoites are much more sensitive to inactivation by chlorine and other disinfectants used to treat drinking water. A dose of chlorine of 1.0 mg/liter with a free chlorine residual of 0.25 mg/liter after 30 minutes resulted in a 99.99% reduction of trophozoites (Cursons *et al.*, 1980) of *A. castellanii* at pH 7.0 and 25°C. A similar reduction with a dose of chlorine dioxide of 2.9 mg/liter (0.65 mg/liter after 30 minutes) was achieved with chlorine dioxide, and an ozone dose of 6.75 mg/liter (residual 0.078 mg/liter after 30 minutes). The experiments were conducted in distilled water. Thus, although the trophozoites are inactivated by these disinfectants, they are significantly more resistant than bacteria. The resistance of *A. castellanii* to chlorine has been shown to add to the resistance of *Legionella pneumophila* growing within the *Acanthamoeba* and may play a significant role in the survival of opportunistic bacteria and their ecology and persistence in distribution systems, cooling towers, hot tubs, and other environments. Kilvington and Price (1990) found that *A. polyphaga* were found to protect the legionellas from at least 50 mg/liter of free chlorine. Control of *Acanthamoeba* in distribution systems may be necessary for control of *Legionella pneumophila* and *Mycobacterium avium*.

6.4 Dose Response

Badenoch *et al.* (1990) demonstrated *Acanthamoeba* infections could be induced in the rat cornea by co-inoculation with the bacterium *Corynebacterium xerosis*. The co-inoculation with *C. xerosis* was necessary to induce the *Acanthamoeba* infection. Infection resulted in 7 of 24 rats that were exposed to 10³ trophozoites and 1 in 10 animals when exposed to 10⁴ trophozoites. At least 10⁴ *C. xerosis* had to be co-inoculated to achieve these infection rates. The results suggest that at least 10³ trophozoites are necessary to cause *Acanthamoeba* eye infection.

6.5 Risk Characterization

Acanthamoeba eye infections result from a combination of some eye trauma or contact lens use and other potential factors listed in Table 6.2. The concentration of *Acanthamoeba* in tapwater or aquatic environments may enhance the risk of infection (Figure 6.1). *Acanthamoeba* infections in contact lens wearers can be eliminated by proper care of the lens to avoid exposure

Table 6.2 Mechanisms Involved in *Acanthamoeba* Keratitis

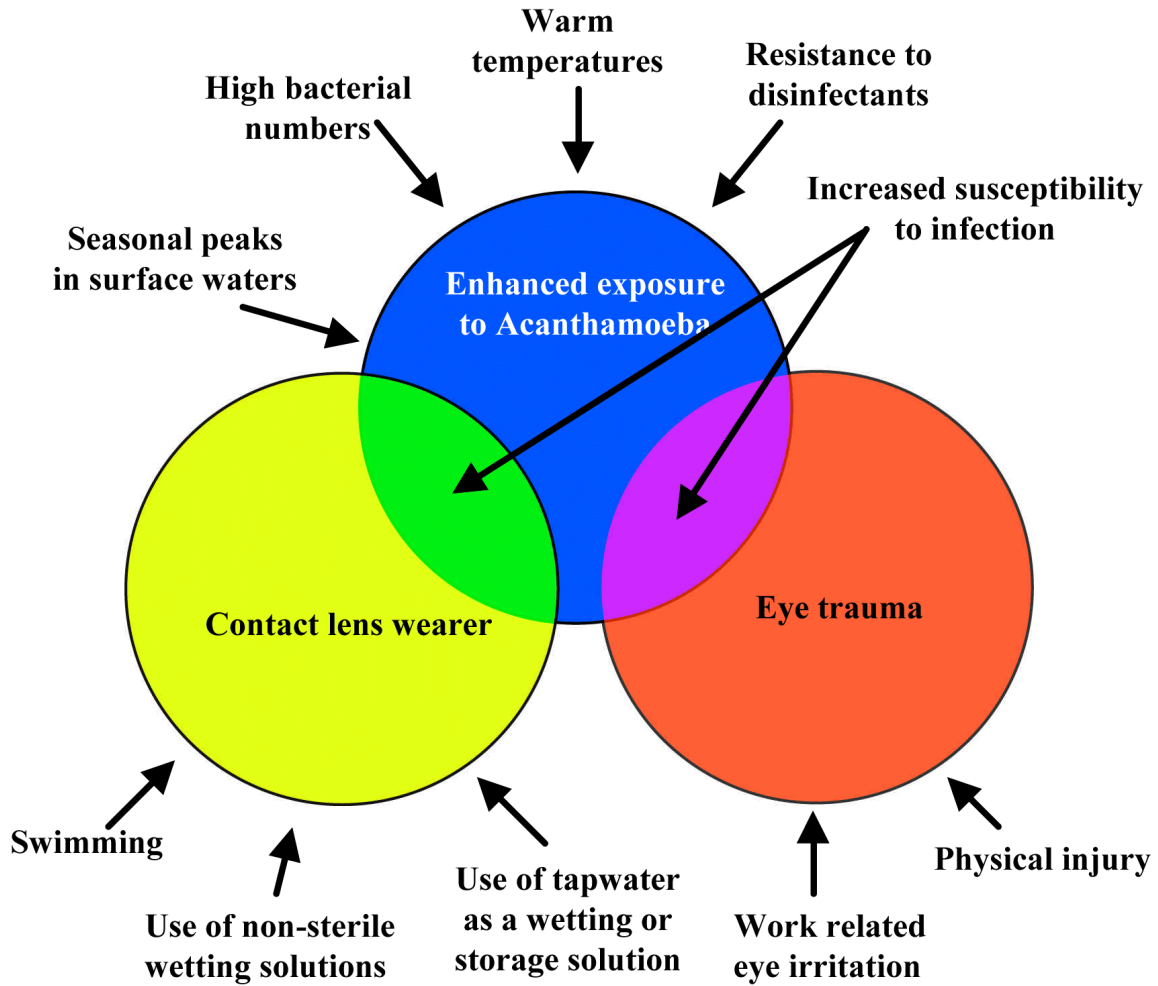
-
- Previous epithelial trauma
 - Virulence of the organism
 - Number of organisms (on the contact lens, in the disinfection fluid, in the contaminated water)
 - Capability of the amoeba to adhere to the cornea
 - Duration of exposure
 - Immune response (presence of antibodies in tears)
-

to the organism. Exposure to contaminated water is the significant risk factor for contact lens wearers. Since *Acanthamoeba* cysts are resistant to inactivation by chlorine, a common disinfectant used for tapwater, exposure of the contact lens to tapwater should be avoided. Proper disinfection of contact lenses and the solutions they come into contact with is essential to prevent infection.

Acanthamoeba may also play a significant role in the potential for transmission of *Legionella pneumophila* and *Mycobacterium avium* via drinking water. The growth of these organisms within *Acanthamoeba* may provide protection from disinfectants and enhance their ability to cause disease in humans. Providing an unsuitable habitat for *Acanthamoeba* could potentially reduce these risks. Low organic matter and disinfectant residuals would be expected to minimize the number of bacteria upon which the amoeba feeds. This amoeba population may also be limited in size, but not necessarily eliminated by adequate disinfectant residuals.

While it is clear that a relationship exists between *Acanthamoeba* in water and keratitis, the role of tapwater is not clearly understood. Data on the occurrence and concentration of *Acanthamoeba* in the United States is lacking. One study suggests that municipal studies which may have become contaminated enhanced the risk of presumed *Acanthamoeba* keratitis (Meier *et al.*, 1998). Seasonal distribution of keratitis and abundance of *Acanthamoeba* in surface waters also suggests a relationship. Additional information on dose needed for infection and quantitative data on occurrence in drinking water supplies would help to better understand the potential risks to contact lens wearers and the general public. The incidence of recognized *Acanthamoeba* keratitis is around 1-2/10⁶ (Table 5.3). The highest incidence in the U.S., which may have been likened to flooding and the use of municipal water supplies, was 14/10⁶ (Meier *et al.*, 1998). Even if all the cases of *Acanthamoeba* were associated with tapwater this would be

Figure 6.1 Eye Trauma and Contact Lenses as Determinants of Susceptibility to *Acanthamoeba* Keratitis



Several conditions, such as use of tapwater as a wetting solution, can increase exposure to *Acanthamoeba*. Individuals who wear contact lenses or have experienced eye trauma are at greater risk to *Acanthamoeba* infections.

less than the 1:10,000 risk of infection per year that EPA has set as the goal for surface water supplies (EPA, 1994; Regli *et al.*, 1991).

7.0 ASSOCIATION OF CONTACT LENSES WITH ACANTHAMOEBIC KERATITIS

7.1 Types of Contact Lenses

Contact lenses are worn on the surface of the eye to correct defects in an individual's vision. The first contact lens, made of glass, was developed in 1887 by Adolf Fick. The modern contact lens was developed in 1948, and is made of plastic and rests on a cushion of tears (Table 7.1). It covers the cornea approximately over the iris and pupil. The hard plastic contact lenses had a limited wearing time because of potential irritation of the cornea. In the 1970's, soft lenses, made from water absorbing plastic gel for greater flexibility, were introduced. In the 1980's extended wear soft lenses, which can be worn without removal for several weeks at a time, were introduced. Soft contact lenses are usually more comfortable because they allow oxygen to penetrate to the surface of the eye. In the 1970's gas permeable hard lenses (which allow more oxygen to reach the eye) were developed.

The Food and Drug Administration must approve all contact lenses before they are available to the public. The types of contact lenses currently in use are listed in Table 7.2.

Table 7.1 History of Contact Lens Development¹

Year	Event
1887	First contact lens made from glass; covers the entire eye
1939	Contact lenses first made from plastic
1948	Plastic contact lenses designed to cover the cornea only
1971	Introduction of soft contact lenses
1978	Introduction of oxygen permeable lenses
1981	Food and Drug Administration approves soft contact lenses for extended (overnight) wear
1986	Overnight wear oxygen permeable lenses become available
1987	Introduction of disposable soft contact lenses

¹Source: Contact Lens Council, 2000

Table 7.2 Types of Contact Lenses

Type	Comments
Daily wear soft lenses	Made of soft, flexible plastics that allow oxygen to pass through to the eye Cleaning is required
Daily wear disposable soft lenses	Typically no lens care is required
Extended wear soft lenses	Available for overnight wear Can usually be prescribed for up to seven days of wear without removal
Extended wear disposable soft lenses	Worn from one to six nights and then discarded Require little or no cleaning
Rigid gas permeable lenses	Made of slightly flexible plastics that allow oxygen to pass through to the eye Vision may be better than with soft lenses Long life (1-2 years) Daily and extended wear available

7.2 Demographics of Contact Lens Use

Currently it is estimated that 34 million Americans wear contact lenses (Contact Lens Council, 2000). Approximately 85% of the wearers use soft contact lenses and 15% use rigid gas permeable. Most wearers use daily wear lenses which are removed at bedtime, while 25% use extended wear lenses (Table 7.3).

Extended wear lenses may be worn overnight and, in some cases, up to a week, before removal. Only 13% of contact lens wearers are 17 years of age or younger (Table 7.4). Most soft contact lenses (45%) are worn by persons 26 to 39 years of age. In contrast, most rigid gas permeable lenses are worn by persons 40 years and older.

Table 7.3 Wearers and Types of Contact Lenses¹

Type of lens	Percent of wearers
Soft lenses	85
Rigid gas permeable	15
Daily wear	75
Extended wear	25

¹Source: Contact Lens Council

Table 7.4 Age Distribution of Contact Lens Wearers in the United States¹

Age (years)	% of soft contact lens wearers	% of rigid gas permeable contact lens wearers
<17	10	3
18 to 25	23	10
26 to 39	45	26
≥40	22	61

¹ Source: Contact Lens Council, 2000

7.3 Risk Factors

The use of contact lenses is the risk factor most commonly associated with acanthamoebic keratitis (Table 7.5). Stehr-Green *et al.* (1987) reported that 85% of the cases were associated with persons who wore contact lenses.

All types of contact lenses have been associated with acanthamoebic keratitis (Table 7.6). Infection results from exposure to contaminated fluids used to wet the contact lens before placement on the eye or the use of contaminated fluids in storage cases. Any contact lens is a potential carrier of *Acanthamoeba* to the eye surface after being exposed to a contaminated fluid.

Table 7.5 Risk Factors Associated with Acanthamoebic Keratitis

Risk Factor	% of Acanthamoebic keratitis cases
Wore contact lenses	85
Wore daily wear lenses	56
Wore extended wear lenses	19
History of corneal trauma	26
History of exposure to contaminated tapwater	25

Table 7.6 Types of Contact Lenses Associated with Acanthamoebic Keratitis

Type of contact lens	Percentage of cases		
	Illingworth <i>et al.</i> , 1995	Stehr-Green <i>et al.</i> , 1987	Moore <i>et al.</i> , 1985
Daily wear soft	21	56	75
Daily wear disposable soft	67	-	-
Extended wear	-	19	14
Hard	8	2	6
Rigid gas permeable	4	7	4

The use of non-sterile solutions such as tapwater, bottled water and non-sterile distilled water have been associated with *Acanthamoeba* infections among contact lens wearers (Moore *et al.*, 1985; Stehr-Green *et al.*, 1987).

Infection is also associated with wearing contact lenses during swimming (Stehr-Green *et al.*, 1987), use of hot tubs or exposure to natural springs (Wilhemus and Jones, 1991). In a case-control study (MMWR, 1987) it was found that of individuals who developed keratitis, 17 of 27 (63%) wore lenses while swimming, while 24 of 81 (30%) did not. Also, patients with keratitis

Table 7.7 Risk Factors for Acanthamoebic Keratitis in Contact Lens Wearers

Risk Factor
Use of tapwater to wet or store lenses
Use of bottled water to wet or store lenses
Use of distilled water to wet or store lenses
Use of non-sterile solutions to wet or store lenses
Wearing lenses during swimming
Wearing lenses in hot tubs
Wearing lenses in natural springs
Use of chlorine to disinfect lenses between uses
Wetting lenses with saliva

were more likely to wet lenses with saliva or wear lenses in a hot tub. The type of disinfectant used to treat the lenses during storage may also affect the risk of keratitis. Chlorine is not an effective means of disinfection and results in a greater risk of keratitis because of *Acanthamoeba* resistance to this disinfectant (Illingworth *et al.*, 1995).

7.4 Contact Lens Disinfection

7.4.1 Studies of Lens Disinfection

Procedures for disinfecting different types of contact lenses and lens equipment have been investigated (Knoll, 1971). Newer and safer methods for lens care were proposed by the U.S. Food and Drug Administration (1973) even before contact lens-associated amoebic keratitis was discovered. Busschaert *et al.* (1978) had found that moist heat sterilization, 80°C for 10 minutes, provided an adequate margin of safety for disinfecting hydrophilic contact lenses. *Acanthamoeba* readily adheres to contact lenses. The degree of adherence depends on water content, surface tension and surface charge (Gorlin *et al.*, 1996). Kilvington (1989) investigated the killing capacity of moist heat against cysts of *A. polyphaga*, which survived a contact time of 60 minutes at 50°C to 60°C; but were inactivated when temperature was increased to 65°C to 70°C. However, when the experimental protocol was tested on lens cases of three patients who used moist heat, not all of the cysts were killed. This study suggested that even when lens cases are cleaned periodically, they probably should be replaced at some frequency to avoid a build up of debris and contaminating microorganisms.

Brandt *et al.* (1989) tested saline solutions, cleaning solutions, and disinfection solutions against three species of *Acanthamoeba* recovered from contact lens cases, *i.e.*, *A. castellanii*, *A. culbertsoni*, and *A. polyphaga*. Although solutions containing hydrogen peroxide were the most effective, cysts were detected in all solutions for at least 6 hours after treatment. The authors concluded that, at the time of their study, none of the solutions available on the market were effective for eliminating cysts of *Acanthamoeba* within a short period of disinfection. Silvany *et al.* (1990) tested *A. castellanii* ATCC 30868 and *A. polyphaga* ATCC 30873 against 13 commercially available solutions. Growth occurred within as few as 30 minutes after exposure to one solution, with growth inhibited for up to 24 hours with five others. Two solutions containing hydrogen peroxide and three containing chlorhexidine inhibited growth within 30 minutes; one solution containing benzalkonium chloride inhibited growth within 1 hour. In this study and others (Brandt *et al.*, 1989), it was concluded that, at that time, there was neither one solution nor one treatment protocol that was effective against all species of *Acanthamoeba*. Rutherford *et al.* (1991) tested chlorhexidine in tablet form to find a procedure that would require less time for cleaning and disinfection. They tested a tablet dissolved in potable water for amoebicidal activity against trophozoites and cysts of *A. castellanii* and *A. polyphaga* isolated from human corneas, and against *A. castellanii* ATCC 30010. None of the amoebae excysted and grew after exposure times of 4, 6, 8, and 24 hours. Results showed that soft contact lenses could be successfully disinfected using tablets and non-sterile tap water. The authors emphasized the fact that water used in this study came from the city of Cleveland, and that water used in other locales should be tested on an individual basis. Kilvington *et al.* (1991) compared three solutions for their ability to kill cysts of *A. castellanii* and *A. polyphaga*: hydrogen peroxide at 0.5, 1.0, and 3.0 percent, chlorhexadine gluconate at 0.004 percent, and thimerosal at 0.0025 percent strength. The assay procedures used in this study showed that hydrogen peroxide at three concentrations and chlorheximide gluconate killed the amoebae while thimerosal at the concentration use did not. Although chlorheximide inactivated 1×10^6 cysts down to approximately 1×10^1 within 4 hours, it was suggested that, although this exposure time was adequate, overnight disinfection probably would be safer.

7.4.2 Hydrogen Peroxide

Hydrogen peroxide is the most effective chemical disinfectant against bacteria and *Acanthamoeba*, including trophozoites and cysts. It acts by oxidizing the organism (Silvany *et al.*, 1990). Hydrogen peroxide does not remove protein from the lens. This requires a separate cleaning process with a separate cleaning solution. Unneutralized hydrogen peroxide carried onto the cornea with the lens causes an acutely painful red eye with sterile inflammatory corneal infiltrates occurring due to oxidative damage to the epithelial surface. Neutralization is best performed after overnight wear in a vented storage case to release liberated oxygen; use of a non-vented case has resulted in serious ocular trauma from explosive propulsion of the lid into the eye. Because some lens wearers forget to neutralize the solution in the storage case in the morning, a one step product has been produced, based on adding a neutralizing tablet to the

storage case when the lenses are placed in the case for disinfection. The problem with these products so far has been the rapid neutralization of the hydrogen peroxide (after 10 minutes). This is insufficient time to kill microbes on the lens.

7.4.3 Multi-Purpose Solutions

Due to problems with hydrogen peroxide, multi-purpose solutions have been produced to clean and store lenses with a single solution without the need for neutralization. This is achieved by combining a poloxomer (detergent) with a chemical disinfectant (PHMB) or polyquaternium with appropriate buffers and EDTA. It is provided as a sterile solution in sufficient quantity for rub and rinse cleaning and storing of the lenses and washing of the storage case. Products may contain from 0.5 to 5ppm of PHMB. The lower concentration is less effective against bacteria and has no activity against *Acanthamoeba*. At this low concentration, eradicating *Acanthamoeba* depends on cleaning by the rinse and rub technique. The higher concentration is most effective against bacteria and fungi and is also acanthamoebicidal for 10² cysts (Seal *et al.*, 1992). Similarly, polyquaternium is used at low concentrations that have poor bactericidal activity and no acanthamoebicidal activity. Multipurpose solutions provide the easiest technique for the lens wearer to clean and disinfect the lens, and give better compliance results. The main advantage of these solutions is that the product is sterile, and there is no need to wash the storage case with tap water. The poloxomers used have a good surfactant action for removal of microbes adhering to the lens. Provided the storage case is changed monthly and tap water contamination is avoided, these solutions represent the most user friendly method. Bactericidal activity is reasonable, but not the best. Use of solutions with PHMB as the disinfectant at a minimum concentration of 5 ppm gives an enhanced microbiocidal effect, including activity against *Acanthamoeba*.

Hiti *et al.*, 2001 recently reported the use of microwaves to inactivate contact lenses contaminated with acanthamoeba. Different types of contact lens cases were contaminated with trophozoites and cysts of three different *Acanthamoeba* species (*A. comandoni*, *A. castellanii*, and *A. hatchetti*) and were exposed to microwave irradiation for various periods of time. Trophozoites, as well as cysts of the different *Acanthamoeba* strains, were effectively killed, even by only 3 minutes of microwave irradiation, and there were no negative effects of irradiation on the contact lens cases themselves.

8.0 DATA GAPS

Risk from *Acanthamoeba* keratitis is complex depending upon the virulence of the particular strain, exposure, trauma or other stress to the eye and host immune response. Bacterial endosymbionts may also play a factor in pathogenicity of *Acanthamoeba*. Which factor(s) may be the most important is not clear. The recent work of Alizadeh *et al.*, (2001) suggests that the ability of the host to produce IgA antibodies may be a significant factor. Thus, immune response could be a deciding factor as it appears in GAE infection and AIDS patients. If so then a certain sub-population with an inability to produce IgA in the tears may be at greatest risk.

No data could be found on the occurrence or types of *Acanthamoeba* in tapwater in the United States. Published work on presence in tapwater does not provide information on the type of treatment the water received or the level of residual chlorine. Assessment of the pathogenicity by cell culture and molecular methods of *Acanthamoeba* in tapwater would also be useful in the risk assessment process for drinking water.

The possibility that *Acanthamoeba* spp. might serve as vectors for bacterial infections from water sources also needs to be explored. The bacterial endosymbionts include an interesting array of pathogens including *Vibrio cholerae* and *Legionella pneumophila*, both of which are well recognized water-borne/water-based pathogens. Work is needed to determine if control of *Acanthamoeba* spp. is needed to control water-based pathogens in water supplies.

Finally, better (i.e. greater range of concentration of cysts) dose response data in animals would be useful to assess the probability of infection of susceptible individuals.

9.0 REFERENCES

- Alizadeh, H., He, Y., McCulley, J.P., Ma, D., Stewart, G.L., Via, M., Haehling, E., and Niederkorn, J. Y. 1995. Successful immunization against *Acanthamoeba* keratitis in a pig model. *Cornea* 14:180-186.
- Alizadeh, H., Apte, S., El-Agha, M.S., Li, L., Hurt, M., Howard, K., Cavanagh, H.D., McCulley, J.P., and Niederkorn, J.Y. 2001. Tear IgA and serum IgG antibodies against *Acanthamoeba* in patients with *Acanthamoeba* keratitis. *Cornea* 20:622-627.
- Anderlini, P., Przepiora, D., Luna, M., Langford, L., Andreeff, M., Claxton, D. and Deisseroth, A.B. 1994. *Acanthamoeba* meningoencephalitis after bone marrow transplantation. *Bone Marrow Transplant.* 14:459-461.
- Asiri, S.M.B.A., Chinnis, R.J. and Banta, W.C. 1990. Potentially pathogenic species of *Acanthamoeba* and *Hartmannella* (Protozoa:Amoebida) in sediment of the Potomac River near Washington, D. C. *J. Helminthol. Soc. Wash.* 57:88-90
- Ayers, K.M., Billups, A.H. and Garner, F.M. 1972. *Acanthamoebiasis* in a dog. *Vet. Pathol.* 9:221-226.
- Badenoch, P.R. 1991. The pathogenesis of *Acanthamoeba* keratitis. *Australian and New Zealand J. Ophthalmol.* 19:9-20.
- Badenoch, P.R., Johnson, A.M., Christy, P.E., and Coster, D.J. 1990. Pathogenicity of *Acanthamoeba* and a *Corynebacterium* in the. *Arch. Ophthalmol.* 108:107-112.
- Bauer, R.W., Harrison, L.R., Watson, C.W., Styer, E.L., and Chapman, W.L., Jr. 1993. Isolation of *Acanthamoeba* sp. from a greyhound with pneumonia and granulomatous amebic encephalitis. *J. Vet. Diagn. Invest.* 5:386-391.
- Berger, S.T., Mondino, B.J., Hoft, R.H., Donzis, P.B., Holland, G.N., Farley, M.K., and Levenson, J.E. 1990. Successful medical management of *Acanthamoeba* keratitis. *Am. J. Ophthalmol.* 110:395-403.
- Booton, G.C., Dykova, I., Lorn, J., Schroeder-Diedrich, J.M. and Byers, T.J. 1999. Morphological and rDNA similarities of *Acanthamoeba* strains parasitic in fish and those causing human disease. *J. Eukaryotic Microbiol.* 46:6A.

- Borochovitz, D., Martinez, A. J., and Patterson, G.T. 1981. Osteomyelitis of a bone graft of the mandible with *Acanthamoeba castellanii* infection. *Human Pathol.* 12:573-576.
- Bose, K., Ghosh, D.K., Ghosh K.N., Bhattacharya, A. and Das, S.R. 1990. Characterization of potentially pathogenic free-living amoebae in sewage samples of Calcutta, India. *Brazilian J. Med. Biol. Res.* 23:1271-1278.
- Bovee, E.C., Wilson, D.E., and Telford, S.R., Jr. 1961. Some amoebas and ameboflagellates inquilinic in Florida reptiles. *J. Protozool.* 8:15.
- Bowman, E.K., Vass, A.A., Mackowski, R., Owen, B.A., and Tyndall, R.L. 1996. Quantitation of free-living amoebae and bacterial populations in eyewash stations relative to flushing frequency. *Am. Ind. Hyg. Assoc. J.* 57:626-633.
- Brandt, F.H., Ware, D.A. and Visvesvara, G.S. 1989. Viability of *Acanthamoeba* cysts in ophthalmic solutions. *Appl. Environ. Microbiol.* 55:1144-1146.
- Brasseur, G., Favennec, L., Perrine, D., Chenu, J.P., and Brasseur, P. 1994. Successful treatment of *Acanthamoeba* keratitis by hexamidine. *Cornea* 13:459-462.
- Brown, T.J. and Cursons, R.T.M. 1977. Pathogenic free-living amoebae (PFLA) from frozen swimming areas in Oslo, Norway. *Scand. J. Infect. Dis.* 9:237-240.
- Brown, T.J., Cursons, R.T.M., Keys, E.A., Marks, M., and Miles, M. 1983. The occurrence and distribution of pathogenic free-living amoebae in thermal areas of the North Island of New Zealand. *New Zealand J. Marine and Freshwater Res.* 17:59-69.
- Busschaert, S.C., Good, R.C. and Szabocsik, J. 1978. Evaluation of thermal disinfection procedures for hydrophilic contact lenses. *Appl. Environ. Microbiol.* 35:618-621.
- Butt, C.G. 1966. Primary amebic meningoencephalitis. *N. Engl. J. Med.* 274:1473-1476.
- Callicott, J.C., Nelson, E. C., Jones, M.M., dos Santos, J.G., Utz, J.P., Duma, R.J. and Morrison, J.V., Jr. 1968. Meningoencephalitis due to pathogenic free-living amoebae. *J.A.M.A.* 206:579-582.
- Cerva, L. 1971. Studies of limax amoebae in a swimming pool. *Hydrobiologia.* 38:141-161.

- Cerva, L. 1989. *Acanthamoeba culbertsoni* and *Naegleria fowleri*: occurrence of antibodies in man. J. Hyg. Epidemiol. Microbiol. Immunol. 33:99-103.
- Chang, J.C.H., Ossoff, S.F., Lobe, D.C., Dorfman, M.H., Dumais, C.M., Qualls, R.G., and Johnson, J.D. 1985. UV Inactivation of Pathogenic and Indicator Microorganisms. Appl. Env. Micro. 49:1361-1365.
- Cheng, K.H., Leung, S.L., Hoekman, H.W., Beekhuis, W.H., Mulder, P.G.H., and Geerards, A.J.M. 1999. Incidence of contact-lens-associated microbial keratitis and its related morbidity. The Lancet 354:181-185.
- Chu, D.M., Miles, H., Toney, D., Ngyuen, C. and Marciano-Cabral, F. 1998. Amebicidal activity of plant extracts from Southeast Asia on *Acanthamoeba* spp. Parasitol. Res. 84:746-752.
- Cirillo, J.D., Falkow, S., Tompkins, L.S., and Bermudez, L.E. 1997. Interaction of *Mycobacterium avium* with Environmental Amoebae Enhances Virulence. Infect. Immun. 65:3759-3767.
- Cirillo, J.D., Cirillo, S.L., Yan, L., Bermudez, L.E. Falkow, S., and Tompkins, L.S. 1999. Intracellular growth in *Acanthamoeba castellanii* affects monocyte entry mechanisms and enhances virulence of *Legionella pneumophila*. Infect. Immun. 67:4427-4434.
- Cohen, E.J., Buchanan, H.W., Laughrea, P.A., Adams, C.P., Galentine, P.G., Visvesvara, G.S., Folberg, R. Arentsen, J.J., and Laibson, P.R. 1985. Diagnosis and management of *Acanthamoeba* keratitis. Am. J. Ophthalmol. 100:389-395.
- Connor, R., Hay, J., Mead, A.J.C., and Seal, D.V. 1993. Reversal of inhibitory effects of *Acanthamoeba castellanii* lysate for *Legionella pneumophila* using catalase. J. Microbiol. Methods 18:311-316.
- Contact Lens Council. 2000. www.contactlenses.org.
- Crespo, E.P., Mallen M.M., Monica, M.P., Ares, P., Fernandez, M.C.A., and Combarro, M.P.C. 1990. Isolation of amoebae of the genera *Naegleria* and *Acanthamoeba* from public fountains in Galicia (N.W. Spain). Water, Air and Soil Pollution. 53:103-111.
- Cruz, O.A., Sabir, S.M., Capo, H., Alfonso, E.C. 1993. Microbial Keratitis in Childhood. Ophthalmology 100:192-196.

- Culbertson, C.G., Smith, J.W., and Miner, J.R. 1958. *Acanthamoeba*: Observations on animal pathogenicity. *Science*. 127:1506.
- Culbertson, C.G. 1971. The pathogenicity of soil amebas. *Annu. Rev. Microbiol.* 25:231-254.
- Cursons, R.T., Brown, T.J., and Keys, E.A. 1980. Effect of disinfectants on pathogenic free-living amoebae: in axenic conditions. *Appl. Environ. Microbiol.* 40:62-66.
- Cursons, R.T., Brown, T.J., Keys, E.A., Moriarty, K.M., and Till, D. 1980. Immunity to pathogenic free-living amoebae: role of humoral antibody. *Infect. Immun.* 29:401-407.
- Daggett, P.-M. 1982. Microbial Hazards of Diving in Polluted Waters - A Proceedings, pp. 39-42, (R.R. Colwell, ed.). Univ. Md. Sea Grant Publ. No. UM-SG-TS-82-01, Univ. Md., College Park, Md.
- D'Aversa, G., Stem, G.A., and Driebe, W.T. Jr. 1995. Diagnosis and successful medical treatment of *Acanthamoeba* keratitis. *Arch. Ophthalmol.* 113:1120-1123.
- de Jonckheere, J., and Van de Voorde, H. 1976. Differences in Destruction of Cysts of Pathogenic and Nonpathogenic *Naegleria* and *Acanthamoeba* by Chlorine. *Appl. Environ. Microbiol.* 31:294-297.
- de Jonckheere, J.F. 1979a. Pathogenic free-living amoebae in swimming pools: survey in Belgium. *Ann. Microbiol. (Inst. Pasteur)*. 130 B:205-212.
- de Jonckheere, J.F. 1979b. Occurrence of *Naegleria* and *Acanthamoeba* in aquaria. *Appl. Environ. Microbiol.* 38:590-593.
- de Jonckheere, J.F. 1987. Taxonomy. In: Rondanelli, E.G., ed. *Amphizoic Amoebae Human Pathology*. Padua, Italy: Piccin Nuova Libreria, 25-48.
- de Jonckheere, J.F., and Michel, R. 1988. Species identification and virulence of *Acanthamoeba* strains from human nasal mucosa. *Parasitol. Res.* 74:314-316.
- Detterline, J.L., and Wilhelm, W.E. 1991. Survey of pathogenic *Naegleria fowleri* and thermotolerant amebas in federal recreational waters. *Trans. Am. Microsc. Soc.* 110:244-261.

Di Gregorio, C., Rivasi, F., Mongiardo, N., De Rienzo, B., Wallace, S., and Visvesvara, G.S. 1992. *Acanthamoeba* meningoencephalitis in a patient with acquired immunodeficiency syndrome. Arch. Pathol. Lab. Med. 116:1363-1365.

Dive, D., Delattre, J.M., and Leclerc, H. 1982. Occurrence of thermotolerant amoebae in an electric power plant cooling pond. J. Therm. Biol. 7:11-14.

Douglas, M. 1930. Notes on the classification of the amoeba found by Castellani in cultures of a yeast-like fungus. J. Trop. Med. Hyg. 33:258-259.

Dowling, J.N., Saba, A.K., and Glew, R.H. 1992. Virulence factors of the family *Legionellaceae*. Microbiol. Rev. 56:32-60.

Dwivedi, J.N. and Singh, C.M. 1965. Pulmonary lesions in an Indian buffalo associated with *Acanthamoeba* sp. Indian J. Microbiol. 5:31-34.

Dyková, I., Lom, J., Machácková, B. and Sawyer, T.K. 1996. Amoebic infections in goldfishes and granulomatous lesions. Folia Parasitol. 43:81-90.

EPA. Environmental Protection Agency. 1994. Enhanced Surface Water Treatment Rule. Federal Register 59 FR 38832, July 29, 1994.

EPA. Environmental Protection Agency. 1998. Demographic Distribution of Sensitive Population Groups. Office of Science and Technology, Human Ecological Effects Division, Washington, D.C.

Ferrante, A. 1991. Free-living amoebae: pathogenicity and immunity. Parasite Immunol. 13:31-47.

Ficker, L. 1988. *Acanthamoeba* keratitis - the quest for a better prognosis. Eye 2 Supp1:S37- 45.

Fields, B.S., Sanders, G.N., and Barbaree, J.M. et al. 1989. Intracellular multiplication of *Legionella pneumophila* in amoebae isolated from hospital hot water baths. Curr. Microbiol. 18:131-137.

Fields, B.S. 1993. *Legionella* and protozoa: interaction of a pathogen and its natural host. In: Barbaree, J.M., Breiman, R.F. Dufour, A.P. (eds.) *Legionella* current status and emerging perspectives. Washington, D.C. American Society for Microbiology 129.

- Franke, E.D., and Mackiewicz, S. 1982. Isolation of *Acanthamoeba* and *Naegleria* from the intestinal contents of freshwater fishes and their potential pathogenicity. *J. Parasitol.* 68:164-166.
- Friedland, L.R., Raphael, S.A., Deutsch, E.S., Johal, J., Martyn, L.J., Visvesvara, G.S., and Lischner, H.W. 1992. Disseminated *Acanthamoeba* infection in a child with symptomatic human immunodeficiency virus infection. *Pediatric Inf. Dis. J.* 11:404-407.
- Fritsche, T.R., Sobek, D., and Gautom, R.K. 1998. Enhancement of in vitro cytopathogenicity by *Acanthamoeba* spp. following acquisition of bacterial endosymbionts. *FEMS Microbiology Letters* 166:231-236.
- Fritsche, T.R., Horn, M., Seyedirashsti, S., Gautom, R., Schleifer, K.-H., and Wagner, M. 1999. *In situ* detection of novel bacterial endosymbionts of *Acanthamoeba* spp. phylogenetically related to members of the Order Rickettsiales. *Appl. Environ. Microbiol.* 65:206-212.
- Gardner, H.A., Martinez, A.J., Visvesvara, G.S., and Sotrel, A. 1991. Granulomatous amebic encephalitis in an AIDS patient. *Neurology* 41:1993-1995.
- Gogate, A., Singh, B.N., Deodhar, L.P., and Jhala, H.I. 1984. Primary amoebic meningo-encephalitis caused by *Acanthameoba*. *J. Postgrad. Med.* 30:125-128.
- Gonzalez, M.M., Gould, E., Dickinson, G., Martinez, A.J., Visvesvara, G., Cleary, T.J., and Hensley, G.T. 1986. Acquired immunodeficiency syndrome associated with *Acanthamoeba* infection and other opportunistic organisms. *Arch. Path. Lab. Med.* 110:749-751
- Gordon, S.M., Steinberg, J.P., DuPuis, M.H., Kozarsky, P.E., Nickerson, J.F., and Visvesvara, G.S. 1992. Culture isolation of *Acanthamoeba* species and leptomyxid amebas from patients with amebic meningoencephalitis, including two patients with AIDS. *Clin. Inf. Diseases*, 15:1024-1030.
- Gorlin, A.I., Gabriel, M.M., Wilson, L.A. and Ahearn, D.G. 1996. Binding of *Acanthamoeba* to hydrogel contact lenses. *Current Eye Res.* 15:151-155.
- Griffin, J.L. 1972. Temperature tolerance of pathogenic and nonpathogenic free-living amoebas. *Science.* 178:869-870.
- Gullett, J., Mills, J., Hadley, K., Podemski, B., Pitts, L., and Gelber, R. 1979. Disseminated granulomatous *Acanthamoeba* infection presenting as an unusual skin lesion. *Am. J. Med.* 67:891-896.

- Hamadto, H.H., Aufy, S.M., El-Hayawan, I.A., Saleh, M.H., and Nagaty, I.M. 1993. Study of free living amoebae in Egypt. *J. Egyptian Soc. Parasitol.*, 23:631-637.
- Hamburg, A., and De Jonckheere, J.F. 1980. Amoebic keratitis. *Ophthalmologica* 181:74-80.
- Hay, J., Seal, D.V., Billcliffe, B., Freer, J.H. 1995. Non-culturable *Legionella pneumophila* associated with *Acanthamoeba castellanii* detection of the bacterium using DNA amplification and hybridization. *J. Appl. Bacteriol.* 78:61-65.
- Hay, J., and Seal, D.V. 1994a. Surveying for legionnaire's disease bacterium. *Curr. Opin. Infect. Dis.* 7:479-483.
- Hay, J. and Seal, D.V. 1994b. Monitoring of hospital water supplies for Legionella. *J. Hosp. Infect.* 26:75-78.
- Hiti, K., Walochnik, J., Faschinger, C., Haller-Schober, E.M., and Aspöck, H. 2001. Microwave treatment of contact lens cases contaminated with acanthamoeba. *Cornea* 20:467-470.
- Hoffler, A.S., and Rubel, L.R. 1974. Free-living amoebae identified by cytologic examination of gastrointestinal washings. *Acta Cytol.* 18:59-61.
- Houang, E., Lam, D., Fan, D., and Seal, D. 2001. Microbial keratitis in Hong Kong: relationship to climate, environment and contact-lens disinfection. *Trans. R. Soc. Trop. Med. Hyg.* 95:361-367.
- Illingworth, C.D., Cook, C.D., Karabatsas, C.H., and Easty, D.L. 1995. *Acanthamoeba* keratitis: risk factors and outcome. *Br. J. Ophthalmol.* 79:1078-1082.
- Illingworth, C.D., and Cook, S.D. 1998. *Acanthamoeba* keratitis. *Surv. Ophthalmol.* 42:493-508.
- Ishibashi, Y., Matsumoto, Y., Kabata, T., Watanabe, R., Hommura, S., Yasuraoka, K., and Ishii, K. 1990. Oral itraconazole and topical miconazole with débridement for *Acanthamoeba* keratitis. *Am. J. Ophthalmol.* 109:121-126.
- Jadin, J.-B., Willaert E., and Hermanne, J. 1973. Presence d'amibes limax dans l'intestin de l'homme et des animaux. *Academie Royale des Sciences D'outre Mer. Bull. Seances* 1973-3, Bruxelles, 520-526.

- Jahnes, W.G., Fullmer, H.M., and Li, C.P. 1957. Free living amoebae as contaminants in monkey kidney tissue culture. *Soc. Exp. Biol. Med.* 96:484-488.
- Janitschke, K., Werner, H., and Muller, G. 1980. Examinations on the occurrence of free-living amoebae with possible pathogenic traits in swimming pools. *Zbl. Bakt. I. Abt. Orig. B.* 170:108-122.
- Janitschke, K., Martinez, A.J., Visvesvara, G.S., and Schuster, F. 1996. Animal model *Balamuthia mandrillaris* CNS infection: contrast and comparison in immunodeficient and immunocompetent mice: a murine model of "granulomatous" amebic encephalitis. *J. Neuropathol. Exp. Neurol.* 55:815-821.
- John, D. T., and Howard, M.J. 1995. Seasonal distribution of pathogenic free-living amebae in Oklahoma waters. *Parasitol. Res.* 81:193-201.
- Johns, K.J., O'Day, D.M., and Feman, S.S. 1988. Chorioretinitis in the contralateral eye of a patient with *Acanthamoeba* keratitis. *Ophthalmology* 95:635-639.
- Jones, B.R., McGill, J.I., and Steele, A.D.McG. 1975. Recurrent suppurative kerato-uveitis with loss of eye due to infection by *Acanthamoeba castellanii*. *Trans. Ophthalmol. Soc. U.K.* 95:210-213.
- Jones, D.B., Visvesvara, G.S., and Robinson, N.M. 1975. *Acanthamoeba polyphaga* keratitis and *Acanthamoeba* uveitis associated with fatal meningoencephalitis. *Trans. Ophthalmol. Soc. U.K.* 95:221-232.
- Kadlec, V. 1978. The occurrence of amphizoic amebae in domestic animals. *J. Protozool.* 25:235-237.
- Khan, N.A., Jarroll, E.L., and Paget, T.A. 2001. *Acanthamoeba* can be differentiated by the polymerase chain reaction and simple plating assays. *Curr. Microbiol.* 43:204-208.
- Khan, N.A. 2001. Pathogenicity, morphology, and differentiation of acanthamoeba. *Curr. Microbiol.* 43:391-395.
- Kilvington, S. 1989. Moist-heat disinfection of pathogenic *Acanthamoeba* cysts. *Letters in Appl. Microbiol.* 9:187-189.

- Kilvington, S., and Price, J. 1990. Survival of *Legionella pneumophila* within cysts of *Acanthamoeba polyphaga* following chlorine exposure. *J. Appl. Bacteriol.* 68:519-525.
- Kilvington, S., Larkin D.F.P., White, D.G., and Beeching, J.R. 1990. Laboratory investigation of *Acanthamoeba* keratitis. *J. Clin. Microbiol.* 28:2722-2725.
- Kilvington, S., Anthony, Y., Davies, D.J.G., and Meakin, B.J. 1991. Effect of contact lens disinfectants against *Acanthamoeba* cysts. *Rev. Inf. Dis.* 13: (Suppl. 5)S414-415.
- King, C.H., Shotts, E.B. Jr., Wooley, R.E., and Porter, K.G. 1988. Survival of coliforms and bacterial pathogens within protozoa during chlorination. *Appl. Environ. Microbiol.* 54:3023-3033.
- Kingston, D., and Warhurst, D.C. 1969. Isolation of ameba from air. *J. Med. Microbiol.* 2:27-36.
- Knoll, H.A. 1971. Microbiology and hydrophilic contact lenses. *Am. J. Optom. Arch. Am. Acad. Optom.* 48:840-844.
- Kong, H.H., Kim, T.H., and Chung, D.I. 2000. Purification and characterization of a secretory serine proteinase of *Acanthamoeba healyi* isolated from GAE. *J. Parasitol.* 86:12-17.
- Kyle, D.E. and Noblet, G.P. 1987. Seasonal distribution of thermotolerant free-living amoebae. II. Lake Issaqueena. *J. Protozool.* 34:10-15.
- Larkin, D.F., Kilvington, S., and Dart, J.K. 1992. Treatment of *Acanthamoeba* keratitis with polyhexamethylene biguanide. *Ophthalmology* 99:185-191.
- Lawande, R.V., Abraham, S.N., John, I. and Egler, L.J. 1979. Recovery of soil amebas from the nasal passages of children during the dusty harmattan period in Zaria. *Am. J. Clin. Pathol.* 71:201-203.
- Ledee, D.R., Hay, J., Byers T.J., Seal, D.V., and Kirkness, C.M. 1996. *Acanthamoeba griffini*. Molecular characterization of new corneal pathogen. *Invest. Ophthalmol. & Visual Sci.* 37:544-550.
- Lengy, J., Jakovljevic, R., and Talis, B. 1971. Recovery of a hartmannelloid ameba from a purulent ear discharge. *Harefuah* 80:23-24.

Lindquist, T.D., Sher, N.A., and Doughman, D.J. 1988. Clinical signs and medical therapy of early *Acanthamoeba* keratitis. *Arch. Ophthalmol.* 106:73-77.

Ly, T.M., and Muller, H.E. 1990. Ingested *Listeria monocytogenes* survive and multiply in protozoa. *J. Med. Microbiol.* 33:51-54.

Lyons, T.B., and Kapur, R. 1977. *Limax* amoebae in public swimming pools of Albany, Schenectady, and Rensselaer counties, New York: Their concentration, correlations, and significance. *Appl. Environ. Microbiol.* 33:551-555.

Ma, P., Visvesvara, G.S., Martinez, A.J., Theodore, F.H., Daggett, P.-M., and Sawyer, T.K. 1990. *Naegleria* and *Acanthamoeba* infections: Review. *Rev. Inf. Diseases.* 12:490-513.

Mannis, M.J., Tamaru, R., Roth, A.M., Burns, M., and Thirkill, C. 1986. *Acanthamoeba* sclerokeratitis. Determining diagnostic criteria. *Arch. Ophthalmol.* 104:1313-1317.

Marciano-Cabral, F., Puffenbarger, R., and Cabral, G.A. 2000. The increasing importance of *Acanthamoeba* infections. *J. Eukaryot. Microbiol.* 47:29-36.

Martinez, A.J. 1977. Free-living amebic meningoencephalitis: comparative study. *Neurol. Neurocir. Psiquiatr.* 18:391-401.

Martinez, A.J., Sotelo-Avila, C., Garcia-Tamayo, J., Moron, J.T., Willaert, E., and Stamm, W.P. 1977. Meningoencephalitis due to *Acanthamoeba* SP. Pathogenesis and clinico-pathological study. *Acta Neuropathol.* 37:183-191.

Martinez, A.J. Is *Acanthamoeba* encephalitis an opportunistic infection? *Neurology* 30:567-574.

Martinez, A.J. 1982. *Acanthamoebiasis* and immunosuppression. Case Report. *J. Neuropathol. Exp. Neurology.* 41:548-557.

Martinez, A.J. 1985. *Free-living Amebas: Natural History, Prevention, Diagnosis, Pathology, and Treatment of Disease.* CRC Press, Inc. Boca Raton, FL 33431, 156 pp.

Martinez, A.J., and Janitschke, K. 1985. *Acanthamoeba*, an opportunistic microorganism: A review. *Infection.* 13:251-256.

Martinez, A.J., and Visvesvara, G.S. 1991. Laboratory diagnosis of pathogenic free-living amoebas: *Naegleria*, *Acanthamoeba*, and *Leptomyxid*. *Clin. Lab. Med.* 11:861-872.

- Martinez, A.J. 1993. Free-living amebas: Infection of the central nervous system. *Mt. Sinai J. Med.* 60:271-278.
- Martinez, A.J., and Visvesvara, G.S. 1997. Free-living, amphizoic and opportunistic amebas. *Brain Pathol.* 7:583-598.
- Martinez, A.J., Visvesvara, G.S., and Chandler, F.W. 1997. Free-living amebic infections. pp.1163-1176 In: *Pathology of Infectious Diseases, Vol. II*, Connor, D.H., Chandler, F.C., Schwartz, D.A., Manz, H.J., Lack, E.E. (eds.) Appleton & Lange Publ.
- Martinez, A.J., and Visvesvara, G.S. 2001. *Balamuthia mandrilllis* infection. *J. Med. Microbiol.* 50:205-207.
- Mathers, W.D., Sutphin, J.E., Folberg, R., Meier, P.A., Wenzel, R.P., and Elgin, R.G. 1996. Outbreak of keratitis presumed to be caused by *Acanthamoeba*. *Am. J. Ophthalmol.* 121:129-142.
- McConnell, E.E., Garner, F.M. and Kirk, J.H. 1968. Hartmannellosis in a bull. *Pathol. Vet.* 5:1-6.
- McCulley, J.P., Alizadeh, H., and Niederkorn, J.Y. 1995. *Acanthamoeba* keratitis. *CLAO J* 21:73-76.
- Mehta, A.P., and Guirges, S.Y. 1979. Acute amoebic dysentery due to free-living amoebae treated with metronidazole. *J. Trop. Med. Hyg.* 82:134-136.
- Meier, P.A., Mathers, W.D., Sutphin, J.E., Folberg, R., Hwang, T., and Wenzel, R.P. 1998. An Epidemic of Presumed *Acanthamoeba* Keratitis That Followed Regional Flooding. Results of a Case-Control Investigation. *Arch. Ophthalmol.* 116:1090-1094.
- Michel, R., Müller, K.-D., Amann, R., and Schmid, E.N. 1998. *Legionella-like* slender rods multiplying within a strain of *Acanthamoeba* sp. isolated from drinking water. *Parasitol. Res.* 60:84-88.
- MMWR. 1987. *Acanthamoeba* keratitis in soft-contact-lens wearers. Centers for Disease Control, Atlanta, Georgia. 36:397-404.
- Moore, M.B., and McCulley, J.P. 1989. *Acanthamoeba* keratitis associated with contact lenses: six consecutive cases of successful management. *Br. J. Ophthalmol.* 73:272-275.

Moore, M.B., McCulley, J.P., Luckenbach, M., Gelender, H., Newton, C., McDonald, M.B., and Visvesvara, G.S. 1985. *Acanthamoeba* keratitis associated with soft contact lenses. Am. J. Ophthalmol. 100:396-403.

Moura, H., Wallace, S., and Visvesvara, G.S. 1992. *Acanthamoeba healyi*, n.sp. and isoenzyme and immunoblot profiles of *Acanthamoeba* spp., Groups II and III. J. Protozool. 39:573-583.

Munson, D.M. 1993. The distribution of cyst-forming amoebae from inshore and freshwater Bermuda sediments. Trans. Am. Microscop. Soc. 112:88.

Nagington, J., Watson, P.G., Playfair, T.J., McGill, J., Jones, B.R., and Steele, A.D.McG. 1974. Amoebic infection of the eye. Lancet. 2:1537-1540.

Nerad, T. 1993. Catalogue of Protists 18th ed., American Type Culture Collection, Manassas, VA.

O'Dell, W.D. 1979. Isolation, enumeration and identification of amebae from a Nebraska lake. J. Protozool. 26:265-269.

Ofori-Kwakye S.K., Sidebottom, D.G., Fischer, H.J., Visvesvara, G.S. 1986. Granulomatous brain tumor caused by *Acanthamoeba*: a case report. J. Neurosurg. 1986, 64:505-509.

O'Malley, M.L., Lear, D.W., Adams, W.N., Gaines, J., Sawyer, T.K., and Lewis, E.J. 1982. Microbial contamination of continental shelf sediments by wastewater. J. Water Pollut. Cntrl. Fed. 54:1311-1317.

Ormerod, L.D., and Smith, R.E. 1986. Contact lens-associated microbial keratitis. Arch. Ophthalmol. 104:79-83.

Page, F.C. 1967. Re-definition of the genus *Acanthamoeba* with description of three species. J. Protozool. 14:709-724.

Page, F.C. 1976. An Illustrated Key to Freshwater and Soil Amoebae. Freshwater Biological Association. The Ferry House, Ambleside, Cumbria LA220LP, England.

Page, F.C. 1988. A New Key to Freshwater and Soil Gymnamoebae with Instructions for Culture. Freshwater Biological Association. The Ferry House, Ambleside, Cumbria LA220LP, England.

- Park, C.H., Iyengar, V., Hefter, L., Pestaner, J.P., and Vandell, N.M. 1994. Cutaneous *Acanthamoeba* infection associated with acquired immunodeficiency syndrome. *Lab. Med.* 25:386-388.
- Penas-Ares, M., Paniagua-Crespo, E., Madrinan-Choren, R., Marti-Mallen, M., Arias-Fernandez, M.C. 1994. Isolation of free-living pathogenic amoebae from thermal spas in N.W. Spain. *Water, Air and Soil Pollution.* 78:83-90.
- Pussard, M., and Pons, R. 1977. Morphologie de la paroi kystique et taxonomie du genre *Acanthamoeba* (Protozoa, Amoebida). *Protistologica.* 13:557-598.
- Radford, C.F., Lehmann, O.J., and Dart, J.K.G. 1998. *Acanthamoeba* keratitis: multicentre survey in England 1992-6. *Br. J. Ophthalmol.* 82:1387-1392.
- Regli, S., Rose, J.B., Haas, C.N., and Gerba, C.P. 1991. Modeling the risk from *Giardia* and viruses in drinking water. *J. Amer. Water Works Assoc.* 83:76-84.
- Rivera, F., Ortega, A., Lopez-Ochotorena, E. and Paz, M.E. 1979. A quantitative morphological and ecological study of protozoa polluting tap water in Mexico City., *Trans. Amer. Microscop. Soc.* 98:465-469.
- Rivera, F., Ramirez, P. Vilaclara, G., Robles, E., and Medina, F. 1983. A survey of pathogenic and free-living amoebae inhabiting swimming pool water in Mexico City. *Environ. Res.* 32:205-211.
- Rivera, F., Galvan, M., Robles, E., Leal, P., Gonzalez, L., and Lacy, A.M. 1981. Bottled mineral waters polluted by protozoa in Mexico. *J. Protozool.* 28:54-56.
- Rivera, F., Roy-Ocotla, G., Rosas, I., Ramirez, E., Bonilla, P., and Lares, F. 1987. Amoebae isolated from the atmosphere of Mexico City and environs. *Environ. Res.* 42:149-154.
- Rivera, F., Lares, F., Ramirez, E., Bonilla, P., Rodriguez, S., Labastida, A., Ortiz, R., and Hernandez, D. 1991. Pathogenic *Acanthamoeba* isolated during an atmospheric survey in Mexico City. *Microbiology of Acanthamoeba: Extended Abstracts. Rev. Inf. Dis.* 13(Suppl. 5):S388- 389.
- Rodriguez-Zaragoza, S. 1994. Ecology of Free-Living Amoebae. *Crit. Rev. Micro.* 20:225-241.

Rohr, U., Weber, S., Michel, R., Selenka, F., and Wilhelm, M. 1998. Comparison of free-living amoebae in hot water systems of hospitals with isolates from moist sanitary areas by identifying genera and determining temperature tolerance. *Appl. Environ. Microbiol.* 64:1822-1824.

Rowan-Kelly, B., and Ferrante, A. 1984. Immunization with killed *Acanthamoeba culbertsoni* - antigen and amoeba culture supernatant antigen in experimental *Acanthamoeba* meningoencephalitis. *Trans. R. Soc. Trop. Med. Hyg.* 78:179-182.

Rowbotham, T.J..1980. Preliminary report on the pathogenicity of *Legionella pneumophila* for freshwater and soil amoebae. *J. Clin. Pathol.* 33:1179-1183.

Rude, R.A., Jackson, G.J., Bier, J.W., Sawyer, T.K., and Risty, N.G. 1984. Survey of fresh vegetables for nematodes, amoebae, and *Salmonella*. *J. Assoc. Off. Anal. Chem.* 67:613-615.

Rutherford, I., Katanik, M.T., and Meisler, D.M. 1991. Efficacy of a chlorhexadine tablet system for disinfection of soft contact lenses against *Acanthamoeba* species. *Rev. Inf. Diseases.* 13(suppl. 5):S416-417.

Sawyer, T.K. 1971. *Acanthamoeba griffini*, a new species of marine amoeba. *J. Protozool.* 18:650-654.

Sawyer, T.K. 1992. Distribution of microbial agents in marine ecosystems as a consequence of sewage-disposal practices. pp. 239-262. In: A. Rosenfield & R. Mann (eds.), *Disposal of Living Organisms into Aquatic Ecosystems*. Maryland Sea Grant College, Univ. MD Systems, College Park, MD.

Sawyer, T.K., Visvesvara, G.S., and Harke, B.A. 1977. Pathogenic amoebas from brackish and ocean sediments, with a description of *Acanthameoba hatchetti*, n.sp. *Science.* 196:1324-1325.

Sawyer, T.K., Nerad, T.A., and G.S. Visvesvara. 1992. *Acanthamoeba jacobsi* sp. n. (Protozoa:Acanthamoebidae) from sewage contaminated ocean sediments. *Proc. Helminthol. Soc. Wash.* 59:223-226.

Sawyer, T.K., Lewis, E.J., Galassa, M., Lear, D.W., O'Malley, M.L., Adams, W.N., and Gaines, J. 1982. Pathogenic amoebae in ocean sediments near wastewater sludge disposal sites. *J. Water Pollut. Cntrl. Fed.* 54:1318-1323.

Schaumberg, D.A., Snow, K.K., and Dana, M.R. 1998. The epidemic of *Acanthamoeba* keratitis: where do we stand? *Cornea* 17:3-10.

- Schmöller, H. 1964. Beschreibung einiger Kulturamoeben mariner Herkunft. J. Protozool. 11:497-502.
- Schuster, F.L., and Jacob, L.S. 1992. Effects of magainins on ameba and cyst stages of *Acanthamoeba polyphaga*. Antimicrob. Agents Chemother. 36:1263-1271.
- Schuster, F.L. and Visvesvara, G.S. 1998. Efficacy of novel antimicrobials against clinical isolates of opportunistic amebas. J. Euk. Microbiol. 45:612-618.
- Seal, D., Stapleton, F., and Dart, J. 1992. Possible environmental sources of *Acanthamoeba* spp. in contact lens wearers. Br. J. Ophthalmol. 76:424-427.
- Seal, D., Hay, J., Kirkness, C., Morrell, A., Booth, A., Tullo, A., Ridgway, A., and Armstrong, M. 1996. Successful medical therapy of *Acanthamoeba* keratitis with topical chlorhexidine and propamidine. Eye. 10:413-421.
- Seal, D. V. 2000. Contact-lens-associated microbial keratitis in the Netherlands and Scotland. The Lancet 355:143-144.
- el Sibae, M.M. 1993. Detection of free-living amoeba (*Acanthamoeba polyphaga*) in the air conditioning systems. J. Egypt. Soc. Parasitol. 23:687-690.
- Silvany, R.E., Dougherty, J.M., McCulley, J.P., Wood, T.S., Bowman, R.W. and Moore, M. B. 1990. The effect of currently available contact lens disinfection systems on *Acanthamoeba castellanii* and *Acanthamoeba polyphaga*. Ophthalmol. 97:286-290.
- Simitzis-LeFlohic, A.M., and Chastel, C. 1982. Le petits mammiferes sauvages: vecteurs d'amibes libres? Med. Tropicale. 42:275-279.
- Singh, B.N. 1952. Nuclear division in nine species of small free-living amoebae and its bearing on the classification of the order Amoebida. Phil. Trans. Royal Soc. London. 236:405-460.
- Singh, B.N., and Das, S.R. 1970. Studies on pathogenic and non-pathogenic small free-living amoebae and the bearing of nuclear division on the classification of the order Amoebida. Phil. Trans. Royal Soc. London, B. Biol. Sci. 259:435-476.
- Singh, B.N., and Das, S.R. 1972. Occurrence of pathogenic *Naegleria aerobia*, *Hartmannella culbertsoni* and *H. rhyssodes* in sewage sludge samples of Lucknow. Curr. Sci., 41:277-281.

- Singh, U. and W.A. Petri. 2000. Free-living amebas. pp. 2811-2817. In: G.L. Mandell, J.E. Bennett and R. Dolin (eds.), *Principle and Practice of Infectious Disease*, 5th Ed., Churchill Livingstone, Philadelphia, PA.
- Stehr-Greene, J.K., Bailey, T.M., Brandt, F.H., Carr, J.H., Bond, W.W., and Visvesvara, G.S. 1987. *Acanthamoeba* keratitis in soft contact lens wearers, a case-control study. *J.A.M.A.* 258:57-60.
- Stothard, D.R., Schroeder-Diedrich, J.M., Awwad, M.H., Gast, R.J., Ledee, D.R., Rodriguez-Zaragoza, S., Dean, C.L., Fuerst, P.A., and Byers, T.J. 1998. The evolutionary history of the genus *Acanthamoeba* and the identification of eight new 18S rRNA gene sequence types. *J. Eukaryot. Microbiol.* 45:45-54.
- Szenasi, Z., Endo, T., Yagita, K., and Nagy, E. 1998. Isolation, identification and increasing importance of 'free-living' amoebae causing human disease. *J. Med. Microbiol.* 47:5-16.
- Taylor, P.W. 1977. Isolation and experimental infection of free-living amoebae in freshwater fishes. *J. Parasitol.*, 63:232-237.
- Teknos, T.N., Poulin, M.D. Laruentano, A.M., and Li, K.K. 2000. *Acanthamoeba* rhinosinusitis: characterization, diagnosis, and treatment. *Am. J. Rhinol.* 14:387-391.
- Telang, G.H., Scola, F., Kantor, G.R., Stieritz, D., and Reboli, A.C. 1996. Disseminated *Acanthamoeba* infection in a patient with AIDS. *Inf. Dis. Clin. Practice.* 5:387-389.
- Thamprasert, K., Khunamornpong, S., and Morakote, N. 1993. *Acanthamoeba* infection of peptic ulcer. *Ann. Trop. Med. Parasitol.* 87: 403-405.
- Theodore, F.H., Jakobiec, F.A., Juechter, K.B., Ma, P., Troutman, R.C., Pang, P.M., and Iwamoto, T. 1985. The diagnostic value of a ring infiltrate in *Acanthamoeba* keratitis. *Ophthalmol.* 92:1471-1479.
- Tyndall, R.L., Lyle, M.M., and Ironside, K.S. 1987. The presence of free-living amoebae in portable and stationary eye wash stations. *Am. Ind. Hyg. Assoc. J.* 48:933-934.
- United States Food and Drug Administration. 1973. Microbiological guidelines for new contact lenses. U.S. Food and Drug Administration, Washington, D.C.

van Klink, F., Alizadeh, H., Stewart, G.L., Pidherney, M.S., Silvany, R.E., YuGuang, H., McCulley, J.P., and Niederkorn, J. Y. 1992. Characterization and pathogenic potential of a soil isolate and an ocular isolate of *Acanthamoeba castellanii* in relation to *Acanthamoeba* keratitis. *Curr. Eye Res.* 11:1207-1220.

Visvesvara, G.S. 2001. Personal communication.

Visvesvara, G.S., Jones, D.B., and Robinson, N.M. 1975. Isolation, identification, and biological characterization of *Acanthamoeba polyphaga* from a human eye. *Am. J. Trop. Med. Hyg.* 24:784-790.

Visvesvara, G.S. 1987. Laboratory Diagnosis. In: Rondanelli, E.G., ed. *Amphizoic amoebae human pathology*. Padua, Italy: Piccin Nuova Libreria, 193-215.

Visvesvara, G.S. 1995. Pathogenic and opportunistic free-living amoebae. In: *Manual of Clinical Microbiology*, 6th ed.; P.R. Murray, E.J. Baron, M.A. Pfaller, F.C. Tenover, and R.H. Tenover, eds. pp. 1196-1203. ASM Press, Washington, D.C.

Visvesvara, G.S., Neafie, R.C., and Martinez, A.J. 1997. Pathogenic and opportunistic free-living amoebae. In: *Pathology of Emerging Infections*. Horsburgh, C.R. Jr. and Nelson, A.M. (eds.). Am. Soc. Microbiol., Washington, D.C., pp. 257-267.

Visvesvara, G.S., Mirra, S.S., Brandt, F.H., Moss, D.M., Mathews, H.M., and Martinez, A.J. 1983. Isolation of two strains of *Acanthamoeba castellanii* from human tissue and their pathogenicity and isoenzyme profiles. *J. Clin. Microbiol.* 18:1405-1412.

Volker-Dieben, H.J.M., Bos, H.J., Kok-van Alphen, C.C. 1980. Amebic keratitis in a windsurfer. *Ned. Tijdschr. Geneesk.* 124:1147-1151.

Walker, P.L., Prociw, P., Gardiner, W.G., and Moorehead, D.E. 1986. Isolation of free-living amoebae from air samples and an air conditioner filter in Brisbane. *Med. J. Australia.* 145:175.

Walochnik, J., Obwaller, A., and Aspöck, H. 2000. Correlations between morphological, molecular biological, and physiological characteristics in clinical and nonclinical isolates of *Acanthamoeba* spp. *Appl. Environ. Microbiol.* 66:4408-4413.

Walochnik, J., Haller-Schober, E., Kolli, H., Picher, D., Obwaller, A., and Aspöck, H. 2000. Discrimination between clinically relevant and nonrelevant *Acanthamoeba* strains isolated from contact lens-wearing keratitis patients in Austria. *J. Clin. Microbiol.* 38:3932-3936.

- Wiley, C.A., Safrin, R.E., Davis, C.E., Lampert, P.W., Braude, A.I., Martinez, A.J., and Visvesvara, G.S. 1987. *Acanthamoeba* meningoencephalitis in a patient with AIDS. *J. Inf. Dis.* 155:130-133.
- Wilhelmus, K.R., and Jones, D.B. 1991. Program planning for research on *Acanthamoeba*. *Rev. Infect. Dis. Suppl.* 5:S446-450.
- Wilson, D.E., Bovee, E.C., Bovee, G.J., and Telford, S.R.. Jr. 1967. Induction of amebiasis in tissues of white mice and rats by subcutaneous inoculation of small free-living, inquiline, and parasitic amebas with associated coliform bacteria. *Exper. Parasitol.* 21:277-286.
- Wright, P., Warhurst, D., and Jones, B.R. 1985. *Acanthamoeba* keratitis successfully treated medically. *Br. J. Ophthalmol.* 69:778-782.
- Yammaura, H., Shirasaka, R., Matsumoto, K., Nakai, T., Horikami, H., and Ishii K. 1993. *Acanthamoeba* in house dust. *Jpn. J. Parasitol.* 42:130-133.
- Yamaura, H., Shirasaka, R., Matsumoto, K., Kuwabara, M., Tsuji, M., and Horikami, H. 1993. Isolation of *Acanthamoeba* from sandboxes in Tokyo and Hiroshima City. *Jpn. J. Parasitol.* 42:361-364.
- Yang, Y.F., Matheson, M., Dart, J.K., and Cree, I.A. 2001. Persistence of acanthamoeba antigen following acanthamoeba keratitis. *Br. J. Ophthalmol.* 85:277-280.
- Zagardo, M.T., Castellani, R.J., Zoarski, G.H., and Bauserman, S.C. 1997. Granulomatous amebic encephalitis caused by leptomyxid amebae in an HIV infected patient. *Am. J. Neuroradiology* 18:903-908.